



Diagnostic Value of Trans-vaginal Sono- Elastography in Discrimination of Cervical Neoplasms

**Asmaa Said Mohamed Hedia ^{a*}, Ayman Abd Elaziz El-dorf ^b,
Rania Essam-el-dein Mohamed Ali ^a and Manal Ezzat Badawy ^a**

^a Radiodiagnosis Departments, Faculty of Medicine, Tanta University, Egypt.

^b Gynecology and Obstetric Departments, Faculty of Medicine, Tanta University, Egypt.

Authors' contributions

This work was carried out in collaboration among all authors. All authors read and approved the final manuscript.

Article Information

DOI: 10.9734/JAMMR/2022/v34i1031353

Open Peer Review History:

This journal follows the Advanced Open Peer Review policy. Identity of the Reviewers, Editor(s) and additional Reviewers, peer review comments, different versions of the manuscript, comments of the editors, etc are available here: <https://www.sdiarticle5.com/review-history/85072>

Received 03 February 2022

Accepted 06 April 2022

Published 21 April 2022

Original Research Article

ABSTRACT

Background: Trans-vaginal ultrasound is the most widely used imaging method to screen women with cervical cancer and other cervical masses, due to its wide availability, low cost and no radiation.

Aim of the Work: The purpose of this study is to demonstrate the role of sono-elastography in differentiating benign from malignant cervical masses. Benign tumours are typically soft, but malignant ones are typically hard.

Patients and Methods: The study was carried out on thirty patients, who referred to Tanta Diagnostic Radiology and Medical Imaging Department, for evaluation of clinically suspected cervical masses, during the period from March 2018 till December 2020. Their age ranged from 37 years to 66 years with a mean age of 49.73 (± 7.65 SD) years.

Results: This Prospective study was carried out on thirty patients, who referred to Diagnostic Radiology and Medical Imaging Department, for evaluation of clinically suspected cervical masses. Their age ranged from 37 years to 66 years old with a mean age of 49.73 years (± 7.65 SD).

Conclusions: Transvaginal sonographic elastography is a promising diagnostic tool that can be used in combination with conventional sonography to distinguish malignant from benign endometrial lesions. Both qualitative and quantitative methods can be used to enhance elastography's diagnostic performance, and SR has showed excellent diagnostic performance.

*Corresponding author:

Keywords: Federation of gynecology and obstetrics; magnetic resonance imaging; computed tomography and transvaginal ultrasonography.

1. INTRODUCTION

Worldwide, cervical cancer is the second most common malignancy in women [1]. The diagnosis of uterine cervical cancer is challenging at the early stages of the disease. The most common clinical staging system for uterine cervical cancer is the International Federation of Gynecology and Obstetrics (FIGO), which continues to be the standard for cervical cancer staging and treatment decision-making [2]. It takes into account the results of the physical examination, histopathology results of biopsy, colposcopy, endoscopy (cystoscopy or sigmoidoscopy) and chest radiography [3].

Despite the fact that surgical and modern imaging staging have been shown to be preferable than clinical staging in terms of determining the true severity of disease, none of these techniques have been incorporated into the FIGO staging system to far. In the developing countries, absence of cervical cancer screening is the main cause of the widespread of the, whereas staging methods are not universally comparable, standardized or available to those present in developed countries. Additionally, there is currently a lack of consensus regarding the clinical use of surgical staging and the optimal imaging modalities [4].

Current imaging methods used to assess uterine cervical cancer include the following; magnetic resonance imaging (MRI), computed tomography (CT), and ultrasound. By contrast, CT has a limited contrast resolution for soft tissue, whereas MRI is the optimal modality for cervix examination. However, due to the inconvenience and limits of intrauterine contraceptive devices, MRI is not typically performed promptly. On the other hand, ultrasonography is gaining clinical importance due to its lower cost, shorter time, and potential for similar diagnostic accuracy to MRI [5]. When combined with a high-resolution probe, transvaginal ultrasonography (TVUS) may provide a more detailed view of the uterine cervix and parametrial tissue [6].

The stiffness of malignant tumors may allow for the distinguishing of malignant and benign tumor tissues based on the elasticity compared to the surrounding normal tissues [7]. Real-time ultrasound elastography (USE) is a rapidly growing method that can currently be

performed on standard ultrasound devices using updated software. The essential concept of USE is a non-invasive scanning to measure the elasticity of tissues through the use of returned ultrasonic signals to measure local tissue displacements prior to and post the application of a compressive force [8].

Superimposed colors on the B-mode image indicate the relative stiffness of the tissues in this location. Compression of the tissue can be accomplished with the probes. The resulting deformation of the tissue is used to calculate the elasticity modulus [9].

Stiff tissues deform or strain less than soft tissues when compressed [10]. By exploiting the fact that malignant tissues are stiffer than benign tissues, USE has been demonstrated to distinguish benign from malignant lesions in a variety of organs, including the thyroid, but little effort has been made to detect and diagnose cervical cancer until now [11].

1.1 Aim of the Work

To determine the value of real-time transvaginal sono-elastography in differentiating benign from malignant uterine cervical masses based on their relative tissue stiffness, as determined by superimposing the elasticity colour map on the B-mode image.

1.2 Patients and Methods

This Prospective study was carried out on thirty patients, who referred to Diagnostic Radiology and Medical Imaging Department, for evaluation of clinically suspected cervical masses. Their ages varied between 37 years to 66 years old with a mean age of 49.73 years (± 7.65 SD).

- **Duration of the study**

From March 2018 till December 2020.

- **Inclusion criteria**

- Post-menopause women.
- Married pre-menopause women.
- Patients, who are suspected to have cervical masses by clinical examination.

- **Exclusion criteria**

- Patients with history of radiotherapy.
- Virgin.

- Cases without histopathological results.
 - Patients with cervical cancer associated with vaginal involvement which proved by gynecologist, to avoid infection and vaginal bleeding.
- ✚ In all studied patients, histopathological analysis was performed and considered as the golden standard reference
- ❖ Any unexpected risks that arose during the research were promptly communicated to participants and the ethical committee.
 - ❖ No apparent risks or hazards to the patients included in this study.
 - ❖ Privacy and confidentiality of all patient data are ensured, and each patient file is assigned a unique code number that includes all investigations and data provided.
- **All patients were subjected to**
 - A. Full clinical evaluation by history and clinical examination.
 1. History: complete history taking included age, residency, occupation, Parity, gravidity, previous abortion, previous pregnancy outcomes, history of the presented complain, any relevant past history.
 2. Clinical examination:
 - General examination
 - Local examination

- **Ultrasonographic examination**

The aplio XG system was used to do real-time TV sono-elastography (Toshiba Medical System, Tokyo, Japan) with a 7.0-MH endo-vaginal probe. Patients were instructed to completely empty their bladders and position themselves in the lithotomy position. To avoid cross contamination, using a disposable condom, the TV ultrasonography probe was inserted into the vagina approximately 1cm from the cervix.

The ultrasound machine was switched to B mode, and data were obtained on the location, shape, size, and echogenicity of cervical lesions. Then, Color Doppler was used to determine the lesions' blood supply. The maximum sensitivity for colour Doppler signal detection was applied, enabling for the

identification of extremely low blood flow velocities [12].

The machine was then switched to elastography mode to determine the stiffness of the cervix and lesions. The left hand was used to hold the anterior pelvic wall, while the right hand was used to compress the cervix. The following parameters were used: dynamic range 4; frame rate M; smoothing 2; density 2; noise rejection 2; Persistence 6; frame rejection, 4;. Color overlays were used to represent the malformation on the B-mode images. The colour scale, which runs from blue to red, indicates the relative stiffness or softness of tissue within the region of interest (ROI) as a whole: Green represents tissue with an average strain, dark blue represents hard tissue, light blue represents moderately hard tissue, yellow represents moderately soft tissue, and red represents soft tissue.

Strain ratios were calculated by dividing the lesion's mean strain by the parametrial tissue's mean strain; The anterior pericervical fat was used as a reference tissue in situations when the lesion was located in the anterior cervical wall.; If the lesion was discovered in the posterior cervical wall, the posterior pericervical fat was used as the reference tissue. As a result, it was necessary to obtain sufficient parametrial tissue. If the lesions reached both sides of the pelvic wall, it was impossible to select a reference tissue, as the strain ratio value would be questionable. We feel, however, that uninfiltreated uterine myometrium could be considered as a reference [9].

2. STATISTICAL ANALYSIS

The IBM SPSS software version 20.0 was used to analyse the data entered into the computer. It is located in Armonk, New York (IBM Corporation). Use of numbers and percentages was used to describe qualitative data in this study. You can tell if your data is normally distributed by performing a Kolmogorov-Smirnov test. Mean, standard deviation, median, and interquartile range (IQR) were used to summarise quantitative data (IQR). The obtained data were given a significance level of 5%.

3. RESULTS

This prospective study enrolled thirty patients who were clinically suspected of having cervical masses.

As shown in Table (1) the age of the thirty patients ranged from 30 to 70 years. There are eleven patients with benign lesions, and nineteen patients with malignant lesions.

The mean age of the studied patient was 49.73 (± 7.65 SD) with range (37-66) years. As revealed by Table (2) and Fig. (1). The mean age of patients with benign lesions was 56.45 (± 6.62 SD) with range (45-66) years, while the mean age of cases with malignant masses was 45.84 (± 5.13 SD) with range (37-52) years. Between the two groups of patients studied, a large statistically significant difference in age was detected.

As shown in Table (3) and Fig. (2), most of the studied cases were malignant as revealed by histopathological results (19/30; 63.3%), while patients with benign masses were (11/30; 36.7%). Furthermore, the current study's findings revealed that more than half of the individuals had been histopathologically diagnosed to have squamous cell carcinoma. (53.3%), while chronic cervicitis and adenocarcinoma were detected in 10% of each of them.

As revealed by Table (4) and Fig. (3) the mean size of detected masses of the studied patients was 25.75 (± 13.86 SD) with range (2.3-51.33) cm^3 . The mean size of detected benign lesions was 15.33 (± 10.57 SD) with range (2.3-37.92) cm^3 , while the mean size of detected malignant masses was 31.78 (± 11.96 SD) with range (13.64-51.33) cm^3 . A statistically significant difference in the size of identified masses was observed between the two groups of individuals investigated.

Table (5) and Fig. (4) demonstrated that 17 (56.7%) patients had mild vascular masses, while 6 (20%) patients showed masses with moderate vascularity and 7 (23.3%) had masses with highly vascularity. Moreover, our result revealed that most of patients with mild vascular masses had benign masses (11/17; 64.70%). Additionally all patients with moderate and highly vascularity masses had malignant masses. A statistically significant difference in the vascularity of cervical masses as shown by colour Doppler US was seen between the two groups of patients studied.

Table (6), as well as Figs. (5-7) demonstrate that the mean RI among studied patients was 0.55 (± 0.13 SD) with range (0.33-0.74) while for cases with Benign masses the mean RI was 0.62 (± 0.07 SD) with range (0.51-0.74) and for cases with Malignant masses the mean RI was 0.51 (± 0.14 SD) with range (0.33-0.72). Additionally, the mean Elasticity score among studied patients was 3.43 (± 0.9 SD) with range (2-5) while for cases with Benign masses the mean Elasticity score was 2.55 (± 0.69 SD) with range (2-4) and for cases with Malignant masses the mean Elasticity score was 3.95 (± 0.52 SD) with range (3-5). Also, The mean SR among studied cases was 8.46 (± 6.01 SD) with range (1.1-18.2) while for cases with Benign masses the mean SR was 2.05 (± 0.69 SD) with range (1.1-3) and for cases with Malignant masses the mean SR was 12.18 (± 4.26 SD) with range (3.4-18.2). There was a significant statistical difference between the studied cases in terms of Elasticity score and SR, but no statistical difference in terms of RI.

Table 1. Distribution of the studied patients (n=30) according to age

Age in years	Benign	Malignant	Total
>30 - 40	0	3	3
>40 - 50	1	12	13
>50 - 60	7	4	11
>60 - <70	3	0	3
Total	11	19	30

Table 2. Distribution of the studied patients according to age and histopathological results (N=30)

Age (years)	Benign (N =11)	Malignant (N = 19)	t	p
Min. – Max.	45.0 – 66.0	37.0 – 52.0	4.905	<0.001
Mean \pm SD.	56.45 \pm 6.62	45.84 \pm 5.13		
Median (IQR)	58.0(51.50–61.50)	48.0 (41.50– 50.0)		

Min: Minimum, Max: Maximum, SD: Standard deviation, IQR: Interquartile range, N: Number, t: Student t-test, p: p value for comparing between the studied groups, *: Statistically significant at $p \leq 0.05$

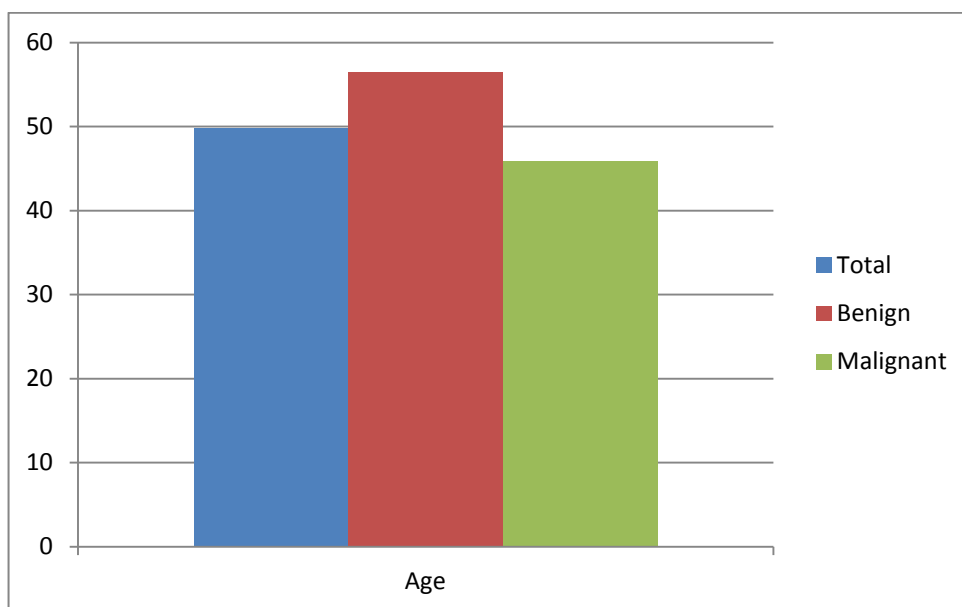


Fig. 1. Distribution of the studied patients according to age and histopathological results

Table 3. Distribution of the studied patients according to histo-pathological results (N=30)

Histopathological Diagnosis	N	%
Benign (N)	11	36.7
Polyps	4	13.3
Chronic cervicitis	3	10.0
Leiomyoma	4	13.3
Malignant (N)	19	63.3
Squamous cell carcinoma	16	53.3
Adenocarcinoma	3	10.0

N: Number, %: percent

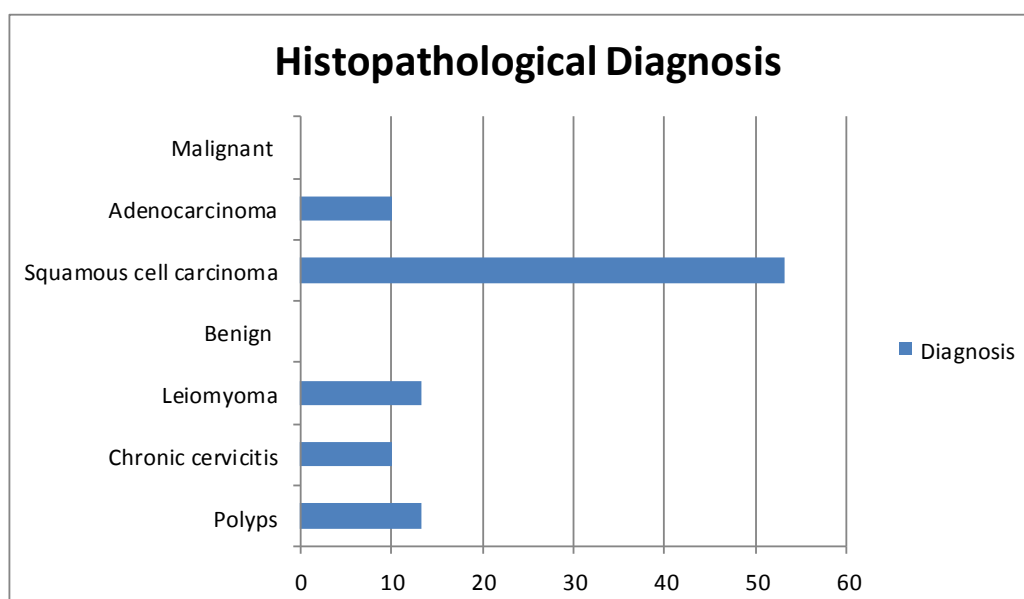


Fig. 2. Distribution of the studied cases according to diagnosis

Table 4. Mean size of the detected masses in the studied patients. (N=30)

Size (cm) of detected masses	Benign (N =11)	Malignant (N = 19)	U	p
Min. – Max. (2.30–51.33)	2.30–37.92	13.64–51.33	31.50	0.001*
Mean ± SD.(25.75±13.86)	15.33±10.57	31.78±11.96		
Median (IQR): 23.80(14.0–36.90)	11.16(9.0–18.66)	33.0(20.97–39.78)		

Min: Minimum, Max: Maximum, SD: Standard deviation, IQR: Interquartile range, N: Number, cm: centimeter, U: Mann Whitney test, p: p value for comparing between the studied groups, *: Statistically significant at $p \leq 0.05$

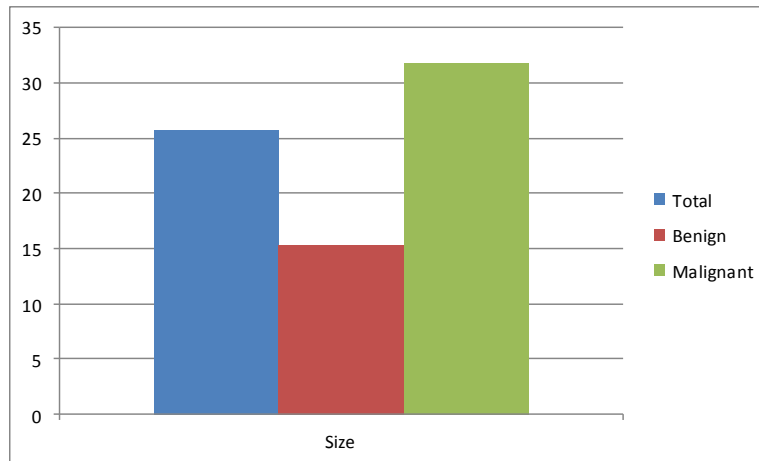


Fig. 3. mean size of the detected masses in the studied patients

Table 5. Distribution of the studied patients according to the vascularity of cervical masses as revealed by color Doppler US (N=30)

Vascularity as revealed by color Doppler US N;%	Benign (N =11)		Malignant (N = 19)		χ^2	MC p
	N	%	N	%		
Mild vascular (17; 56.7)	11	100.0	6	31.6	12.860*	0.001*
Moderate vascular (6; 20.0)	0	0.0	6	31.6		
Highly vascular (7; 23.3)	0	0.0	7	36.8		

N: Number, %: percent, χ^2 : Chi square test, MC: Monte Carlo
 p: p value for comparing between the studied groups, *: Statistically significant at $p \leq 0.05$

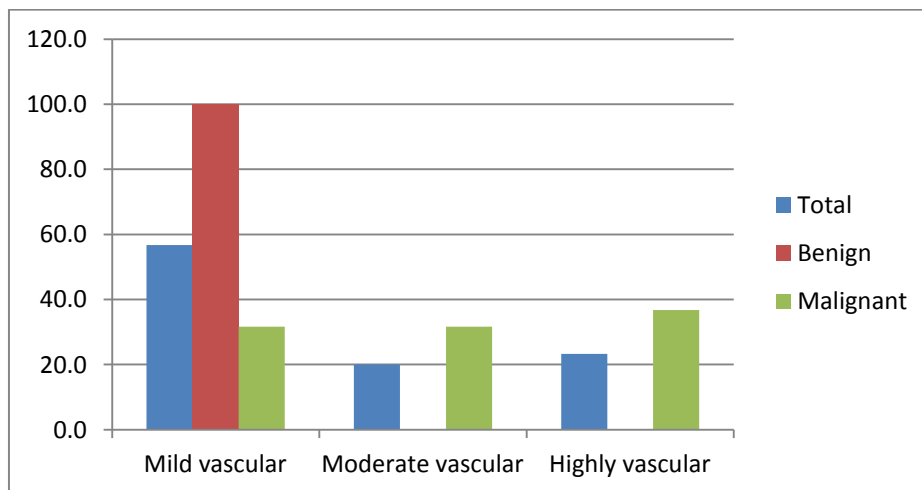


Fig. 4. Distribution of the studied patients according to the vascularity of cervical masses as revealed by color Doppler ultrasound

Table 6. Distribution of the studied patients according to imaging parameters (N=30)

Imaging parameters	Benign (N =11)	Malignant (N = 19)	U	p
RI				
Min. – Max. (0.33 – 0.74)	0.51 – 0.74	0.33 – 0.72	60.0	0.057
Mean ± SD. (0.55 ±0.13)	0.62 ±0.07	0.51 ±0.14		
Median (IQR): 0.57 (0.43–0.68)	0.61 (0.57–0.65)	0.45 (0.40–0.68)		
Elasticity score				
Min. – Max. (2.0 – 5.0)	2.0 – 4.0	3.0 – 5.0	16.0*	<0.001*
Mean ± SD. (3.43 ±0.90)	2.55 ±0.69	3.95 ±0.52		
Median (IQR): 4.0 (3.0–4.0)	2.0(2.0–3.0)	4.0 (4.0–4.0)		
SR				
Min. – Max. (1.10 – 18.20)	1.10 – 3.0	3.40 – 18.20	0.0*	<0.001*
Mean ± SD. (8.46 ±6.01)	2.05 ±0.69	12.18 ±4.26		
Median (IQR): 9.20 (2.50–13.40)	2.20 (1.50–2.50)	12.70 (9.95–15.0)		

RI: Resistive Index, SR: strain Ration, Min: Minimum, Max: Maximum, SD: Standard deviation, IQR: Interquartile range, N: Number, cm: centimeter, U: Mann Whitney test, p: p value for comparing between the studied groups, *: Statistically significant at $p \leq 0.05$

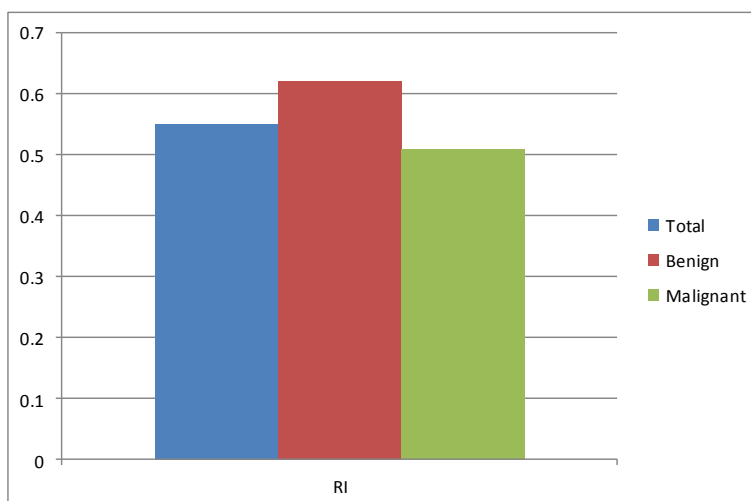


Fig. 5. Distribution of the studied patients according to Resistive Index

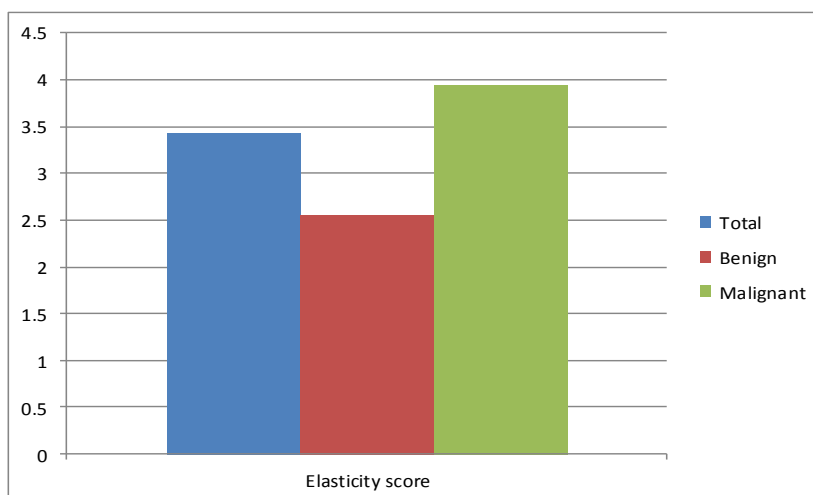


Fig. 6. Distribution of the studied patients according to Elasticity score

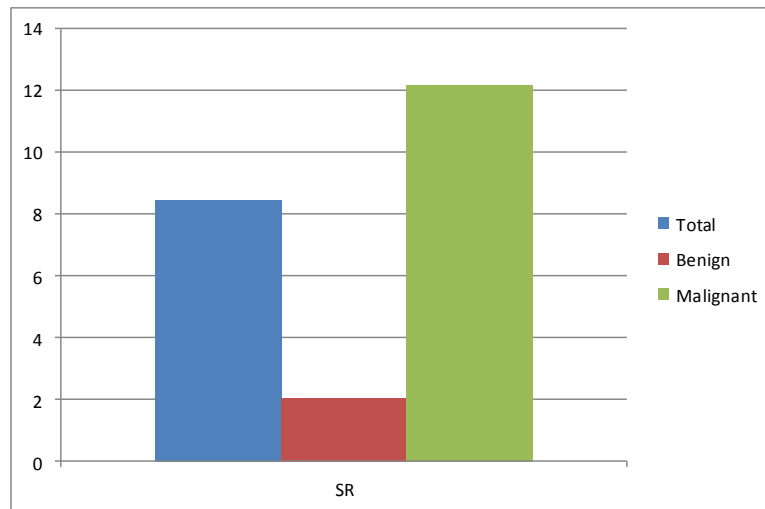
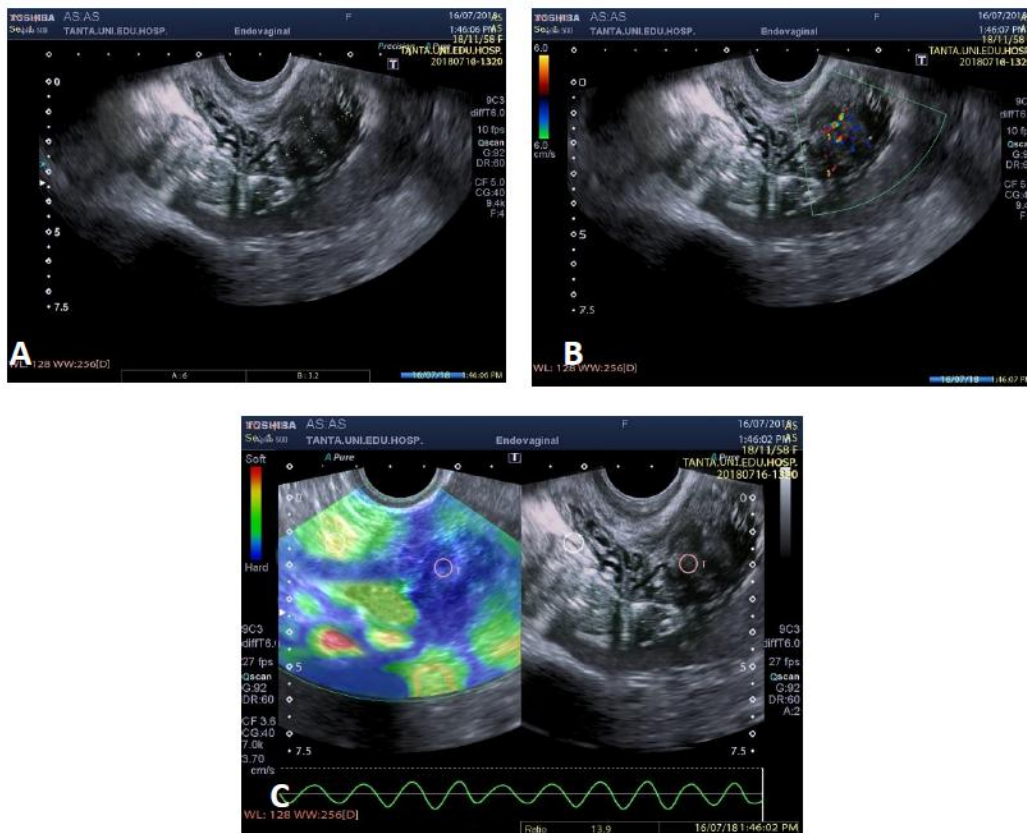
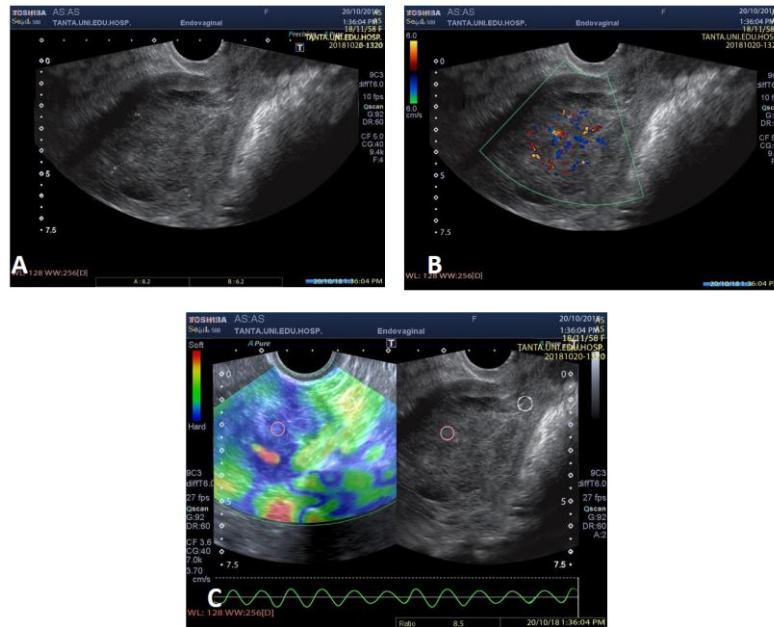


Fig. 7. Distribution of the studied patients according to Strain Ratio

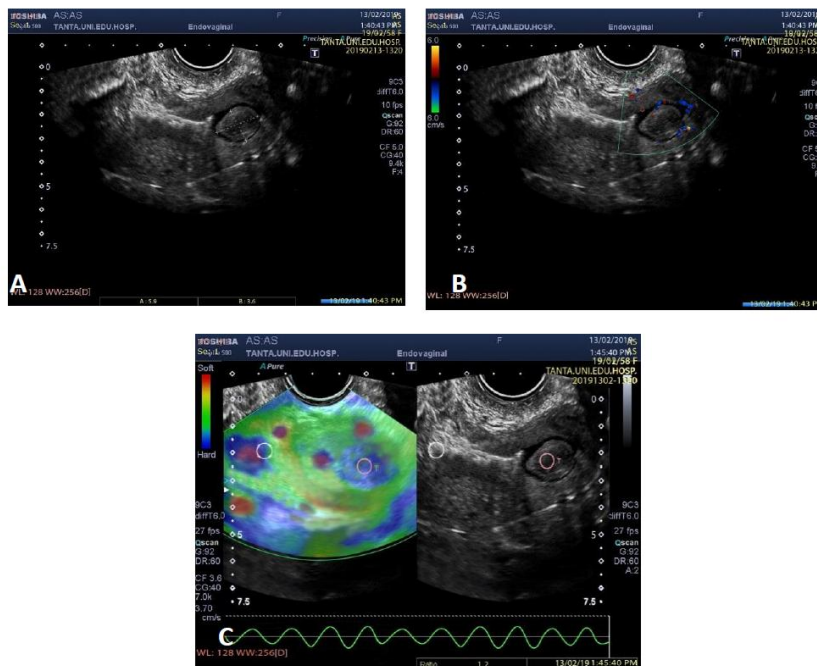
4. CASES



Case 1. A forty-one years old female patient with malignant cervical mass (confirmed to be adenocarcinoma by pathological examination). B-mode ultrasound image (A) shows isoechoic mass infiltrating the uterus measuring 6 X 3.2 cm. Power Doppler image (B) shows moderate vascularity of detected cervical mass. TV elastogram (C) shows that the mass had an elasticity score of 4 and strain ratio was 13.9



Case 2. A fifty-one years old female patient with malignant utrine mass extend to the cervical (Pathological testing confirmed the diagnosis of squamous cell carcinoma).B-mode ultrasound image (A) shows hypoechoic mass infiltrating the uterus measuring 8.2 X 6.2cm. Power Doppler image (B) shows moderate vascularity of detected cervical mass. TV elastogram (C) shows that the mass had an elasticity score of 3 and strain ratio was 8.5



Case 3. A fifty-eight years old female patient with well defined polyp of the cervix (Pathological examination confirmed the diagnosis of benign leiomyoma).B-mode ultrasound image (A) shows isoechoic mass measuring 5.9 X 3.6cm. Power Doppler image (B) shows mild vascularity of detected cervical mass. TV elastogram (C) shows that the mass had an elasticity score of 3 and strain ratio was 1.2

5. DISCUSSION

Real-time USE is a rapidly growing technique that can currently be performed on standard ultrasound devices with updated software. The essential concept of USE is the non-invasive imaging and measurement of tissue elasticity through the use of returned ultrasonic signals to quantify local tissue displacements prior to and following the compressive force application. When pressured, rigid tissues deform or strain less than soft tissues. USE has been found to identify benign from malignant lesions in the gastrointestinal tract, lymph nodes, pancreas, breast, liver, and prostate by exploiting the characteristic that normal tissues have a lower stiffness than malignant tissues (Zhi, et al., 2007) [13].

When applied in combination with a high-resolution probe, the TVUS can offer a more detailed view of the uterine cervix and parametrial tissue. It is generally established that malignant tissues are frequently harder than normal tissues around them, and their elasticity can be used to distinguish benign from malignant tissues (Sun, et al., 2012) [6].

This is why this study was selected to be conducted to assess the role of real-time transvaginal sono-elastography in distinguishing between benign and malignant uterine cervical masses by assessment of their relative tissue stiffness, which were reflected by colors superimposing on the B-mode image.

This Prospective study was carried out on thirty patients, who would be referred to Diagnostic Radiology and Medical Imaging Department, for evaluation of clinically suspected cervical masses on duration from March 2018 until December 2020.

Regarding demographic characteristics, the mean age for total cases was 49.73 (± 7.65 SD) with range (37-66) years while for cases with Benign masses the mean age was 56.45 (± 6.62 SD) with range (45-66) years and for cases with Malignant masses the mean age was 45.84 (± 5.13 SD) with range (37-52) years. There was a significant age difference amongst the cases studied.

One of the most common type of genital tract cancer in women is cervical cancer, with an estimated 150,000 new cases per year and an age-standardized incidence of 8.9 cases per 100,000 women per year in China, particularly among young women. Currently, cervical cancer

is identified mostly using specialised clinical examinations, computed tomography (CT), ultrasound, and MRI. MRI is the ideal modality for the cervix in compared to CT, which has a limited contrast resolution for soft tissue. However, due to the discomfort and limitations of contraceptive devices, it is not always possible to perform MRI immediately. In comparison, ultrasonography is gaining clinical interest due to its reduced time consuming, lower cost, noninvasive, and safety, especially for patients requiring repeated examinations (Zhang, et al., 2011) [14].

The present study shows that the diagnosis of masses was distributed as for 11 (36.6%) benign cases there were 4 (13.3%) Polyps, 3 (10%) Chronic cervicitis and 4 (13.3%) Leiomyoma for 19 (63.3%) Malignant cases there were 16 (53.3%) Squamous cell carcinoma and 3 (10%) Adenocarcinoma. Among the cases there were 14 (46.7%) Hypoechoic, 6 (20%) Mixed echogenicity and 10 (33.3%) Isoechoic. In the Benign cases there were 5 (45.5%) Hypoechoic, 1 (9.1%) Mixed echogenicity and 5 (45.5%) Isoechoic. In the Malignant cases there were 9 (47.4%) Hypoechoic, 5 (26.3%) Mixed echogenicity and 5 (26.3%) Isoechoic. Regarding the echogenicity no statistically significant difference existed between the cases studied.

In the study of Sun, et al., 2012 [6], After TVUS exams, Except for nabothian cysts, thirty-six patients were found to be negative, including six cases of cervical erosion, three cases of cervical polyp, ten cases of inflammation, and seventeen cases of cervical cancer in the early stages. These individuals had a connective and smooth hyperechoic serosa, a definite hypoechoic cervical canal, and a homogeneous cervical stroma except for the anechoic nabothian cysts. TVUS properly detected ten benign lesions cases and 64 malignant lesions cases. Six patients in the benign group had a spot-like echogenic focus surrounding the cervical os. Three cases of cervical erosion and three cases of cervical inflammation were seen in these patients. Two patients with cervical polyps were diagnosed accurately due to the detection of a hyperechoic protrusion in the cervical canal. There were 58 solid masses discovered, including two leiomyomas and 56 cervical carcinomas.

According to Su, et al. 2013 [15], On B-mode sonography, all 58 malignant lesions appeared solid and were hypoechoic. Sensitivity,

specificity, and diagnostic accuracy were 78.95, 77.97, and 78.45 percent, respectively, based on their boundaries, morphologic characteristics, and echoes on color Doppler flow imaging and grey scale sonography.

The term "real-time sono-elastography" refers to a relatively new technology for describing the mechanical properties of tissue. It is comparable to colour Doppler ultrasonography in that it is used to define an area of interest. Colors superimposed on the B-mode image describe the relative stiffness of the tissues within this region. Real-time elastography can be performed with flexible echo-endoscopes, rigid endo-cavitary probes, and transcutaneous linear transducers. Compression of the tissue can be done with the probes. The elasticity modulus is determined by the deformation of the tissue as a result of the deformation (Janssen, et al., 2008) [10].

The current study shows that the mean size among studied cases was 25.75 (± 13.86 SD) with range (2.3-51.33) cms while for cases with Benign masses the mean Size was 15.33 (± 10.57 SD) with range (2.3-37.92) cms and for cases with Malignant masses the mean Size was 31.78 (± 11.96 SD) with range (13.64-51.33) cms. There was a high statistically significant variation in size between the studied cases.

Our findings are confirmed by a study of Shady, et al. 2015 [9] as they reported that All lesions in the patients' group had a mean surface area of 8.35 \pm 4.07 cm². Mean surface areas of the recurrent cancer cervix, primary cancer cervix and fibroid lesions were 5.80 \pm 2.77, 7.68 \pm 3.15 cm² and 12.18 \pm 5.27 cm² respectively.

In the study of Sun, et al. 2012 [6], mean size of these masses was 17.9 \pm 8.1 mm. Two of them developed hydronephrosis or non-functioning kidney. Eight cases of early cervical cancer were found as a result of increased blood supply, despite the absence of an evident hypoechoic mass.

Cervical cancer continues to be a significant public health issue, particularly in developing countries, which account for approximately 85 percent of the global burden of cervical cancer. Doppler ultrasound is critical for assessing the blood flow patterns in the uterine arteries of pre- and postmenopausal women with cervical cancer and other cervical tumours, particularly via the resistive index (RI) (Zaria, et al., 2020) [16].

Among the cases in the study in our hands there were 17 (56.7%) Mild vascular, 6 (20%)

Moderate vascular and 7 (23.3%) Highly vascular. In the Benign cases there were 11 (100%) Mild vascular. In the Malignant cases there were 6 (31.6%) Mild vascular, 6 (31.6%) Moderate vascular and 7 (36.8%) Highly vascular. There was no statistically significant difference in vascularity across the studied cases.

In the study of Shady, et al. 2015 [9], Twenty-four of the twenty-seven primary cancer cervix lesions had high vascularity on power Doppler imaging, four of the five recurring cancer cervix lesions had high vascularity, and none of the eight fibroids had central vascularity with only peripheral vascularity.

Sonoelastography is still the gold standard for diagnosing cervical cancer. In comparison to the gold standard which is cervical biopsy, women are more open to noninvasive examination. A prior study revealed a statistically significant difference in the elasticity of malignant and normal cervical tissue. The elastic modulus of an object increases with its stiffness. Malignant tissues are more rigid than normal tissues. As a result, the former's elastic modulus is bigger than the latter's. Collagen fibres and a few muscle fibres make up the majority of cervical tissues. Although cervical tissues' elasticity may alter under certain physiological situations, such as pregnancy or menstruation, the usual elasticity of cervical tissues does not change with age (Thomas, et al., 2007) [7].

The present study shows that the mean RI among studied cases was 0.55 (± 0.13 SD) with range (0.33-0.74) while for cases with Benign masses the mean RI was 0.62 (± 0.07 SD) with range (0.51-0.74) and for cases with Malignant masses the mean RI was 0.51 (± 0.14 SD) with range (0.33-0.72). The mean Elasticity score among studied cases was 3.43 (± 0.9 SD) with range (2-5) while for cases with Benign masses the mean Elasticity score was 2.55 (± 0.69 SD) with range (2-4) and for cases with Malignant masses the mean Elasticity score was 3.95 (± 0.52 SD) with range (3-5).

The mean SR among studied cases was 8.46 (± 6.01 SD) with range (1.1-18.2) while for cases with Benign masses the mean SR was 2.05 (± 0.69 SD) with range (1.1-3) and for cases with Malignant masses the mean SR was 12.18 (± 4.26 SD) with range (3.4-18.2). There was high statistically significant difference between studied cases as regard Elasticity score and SR and no statistically significant difference as regard RI.

Our results are supported by study of Thomas, et al. 2007 [7] as they reported that Two readers jointly evaluated the colour distribution in all 113 cervixes' ROIs using an analogue scale ranging from 1 (definitely normal) to 5. (definitely abnormal). The readers paid special attention to the presence of focal blue regions (hard tissue) and failure to delineate the cervical contour or anatomic structures such as the cervical canal in their assessment. Subjective scores were significantly different between the cervical lesions group (3.5 0.9) and normal group (1.8 0.7). (P0.000089). Both readers considered the cervical assessment grade classification useful.

Furthermore, Shady, et al. 2015 [9] found that Mean SR of the diseased group was 10.41 ± 2.59 . Mean SR of the control group was 2.46 ± 0.46 . Mean SRs of the cancer cervix, recurrent cancer cervix and fibroid lesions were 11.51, 10.60 and 6.65 respectively. When all SRs were compared, it was shown that the diseased group's mean SR was significantly greater than the control group's (P <0.0001). Additionally, the mean SR of malignant lesions (recurrent and primary cervical cancer) was significantly greater than the mean SR of benign lesions (fibroid) (P <0.0001).

Elastography has established itself as a valuable auxiliary device for sonographic diagnosis. Elastograms are representations of tissue stiffness in grayscale, colour, or a combination of the two. Elastography is most frequently used to diagnose breast lesions, with areas under the receiver operating characteristic curve ranging from 0.88 to 0.95 for differentiating cancer from benign lesions in studies. The method is especially beneficial for diagnosing complex cysts, although the way these lesions are displayed varies between scanners (Garra, et al., 2011) [17].

6. CONCLUSION

The current study shows that Using roc curve, it was shown that RI can be used to diagnose malignant cases with slightly difference but no statistically significant difference (P=0.055) at a cutoff level of ≤ 0.5 , AUC of 0.713, 95% C.I (0.524-0.902), with 57.89% sensitivity, 100% specificity, 100% PPV, 57.9% NPV and 73% accuracy. Using roc curve, it was shown that Elasticity score can be used to diagnose malignant cases with high statistically significant difference (P<0.001*) at a cutoff level of >3, AUC of 0.923, 95% C.I (0.815-1.032), with 84.21%

sensitivity, 90.91% specificity, 94.1% PPV, 76.9.9% NPV and accuracy 86.67%. Using roc curve, it was shown that SR can be used to diagnose malignant cases with high statistically significant difference (P<0.001*) at a cutoff level of >3, AUC of 1.0, 95% C.I (1-1), with 100% sensitivity, 100% specificity, 100% PPV, 100% NPV and accuracy 100%.

CONSENT

All participants in this study provided informed consent.

ETHICAL APPROVAL

All participants in this study provided informed consent.

COMPETING INTERESTS

Authors have declared that no competing interests exist.

REFERENCES

1. World Health Organization. Comprehensive cervical cancer control. A guide to essential practice. WHO, Geneva; 2006.
2. Freeman SJ, Aly AM, Kataoka MY, Addley HC, Reinhold C, Sala E. The revised FIGO staging system for uterine malignancies: implications for MR imaging. *Radiographics*. 2012;32(6):1805-1827.
3. Pecorelli S, Zigliani L, Odicino F. Revised FIGO staging for carcinoma of the cervix. *Int J Gynecol Obstet*. 2009;105:107-108.
4. Loubeyre P, Navarra I, Undurraga M, et al. Is imaging relevant for treatment choice in early stage cervical uterine cancer. *Surge Oncol*. 2012;21(1):1-6.
5. Fischerova D, Cibula D, Stenhova H, et al. Transrectal ultrasound and magnetic resonance imaging in staging of early cervical cancer. *Int J Gynecolog Cancer*. 2008;18:766-772.
6. Sun LT, Ning CP, Liu YJ, Wang ZZ, Kong XC, Tian JW. Is transvaginal elastography useful in pre-operative diagnosis of cervical cancer?. *European Journal of Radiology*. 2012;81(8):e888-e892.
7. Thomas A, Kümmel S, Gemeinhardt O, Fischer T. Real-time sonoelastography of the cervix: tissue elasticity of the normal and abnormal cervix. *Acad Radiol*. 2007;14(2):193-200.

8. Gennisson JL, Deffieux T, Fink M, Tanter M. Ultrasound elastography: principles and techniques. *Diagnostic and Interventional Imaging*. 2013;94(5):487-495
9. Shady M, Abdel Latif M, Nabil H, El-Sadda W. Could trans-vaginal sono-elastography help benign-malignant differentiation of cervical masses?. *The Egyptian Journal of Radiology and Nuclear Medicine*. 2015;46(4):1291-1299.
10. Janssen J. US elastography: Current status and perspectives. *Z Gastroenterol*. 2008;46(6): 572-579.
11. Dietrich CF, Barr RG, Farrokh A, Dighe M, Hocke M, Jenssen C, Havre RF. Strain elastography-how to do it?. *Ultrasound International Open*. 2017;3(4):E137.
12. Latif MA, Shady M, Nabil H, Mesbah Y. Trans-vaginal sono-elastography in the differentiation of endometrial hyperplasia and endometrial carcinoma. *The Egyptian Journal of Radiology and Nuclear Medicine*. 2016;47(3):1123-1131.
13. Zhi H, Ou B, Luo MB, et al. Comparison of ultrasound elastography, mammography, and sonography in the diagnosis of solid breast lesions. *J Ultrasound Med*. 2007;26:807–15.
14. Zhang XJP, Zheng J. Revised FIGO staging of cervical cancer and treatments. *Journal of International Reproductive Health/Family Planning*. 2011;30:153 –154.
15. Su Y, Du L, Wu Y, Zhang J, Zhang X, Jia X, Liu Q. Evaluation of cervical cancer detection with acoustic radiation force impulse ultrasound imaging. *Experimental and Therapeutic Medicine*. 2013;5(6):1715-1719.
16. Zaria IM, Garba I, Dung CN, Oluluke IP, Suleiman L. Doppler ultrasound evaluation of blood flow patterns of the uterine arteries in pre-and postmenopausal women with cervical cancer and controls in Zaria. *West African Journal of Radiology*. 2020;27(1):18.
17. Garra B, S. Elastography: Current status, future prospects, and making it work for you. *Ultrasound quarterly*. 2011;27.3:177-186.

© 2022 Hedia et al.; This is an Open Access article distributed under the terms of the Creative Commons Attribution License (<http://creativecommons.org/licenses/by/4.0>), which permits unrestricted use, distribution, and reproduction in any medium, provided the original work is properly cited.

Peer-review history:

*The peer review history for this paper can be accessed here:
<https://www.sdiarticle5.com/review-history/85072>*