



# Histological Effect of Ethanolic Extracts of Fruits of *Acacia nilotica* and Flowers of *Calotropis procera* on Aspirin Induced Stomach Ulcer in Male Albino Rats

Zuhairah Ismail Muhammad <sup>a\*</sup>, Chinedu Imo <sup>a</sup>,  
Kayode Adebisi Arowora <sup>a</sup> and Philip Shadrach <sup>a</sup>

<sup>a</sup> Department of Biochemistry, Faculty of Pure and Applied Sciences, Federal University, Wukari, Nigeria.

## Authors' contributions

This work was carried out in collaboration among all authors. Authors ZIM, CI and KAA designed the experiment. Authors CI and KAA reviewed the literature. All authors participated in laboratory analysis. Authors ZIM and CI performed the data analysis. All authors read and approved the final manuscript.

## Article Information

DOI: 10.9734/AJBGMB/2023/v14i1305

## Open Peer Review History:

This journal follows the Advanced Open Peer Review policy. Identity of the Reviewers, Editor(s) and additional Reviewers, peer review comments, different versions of the manuscript, comments of the editors, etc are available here: <https://www.sdiarticle5.com/review-history/99691>

Original Research Article

Received: 01/03/2023  
Accepted: 01/05/2023  
Published: 11/05/2023

## ABSTRACT

**Aim:** This study examined the histological effect of ethanolic extracts of fruits of *Acacia nilotica* and flowers of *Calotropis procera* on aspirin-induced stomach ulcer in male albino rats. *Acacia nilotica* fruits and *Calotropis procera* flowers are among the plant parts which are used in the treatment of ulcers by local folks in Wukari, Nigeria.

**Study Design:** Seventy healthy male albino rats were used in this study; they were randomly distributed into 7 groups of 10 animals each. The test animals were induced with ulcer using 500 mg/kg body weight of aspirin and then treated with *Acacia nilotica* fruits and *Calotropis procera* flowers for 5 and 14 days respectively.

\*Corresponding author: E-mail: [zuhairahismail10@gmail.com](mailto:zuhairahismail10@gmail.com);

**Methodology:** This study was carried out in two phases: stomach ulcer was induced in test animals using aspirin and treated for a period of 5 days and 14 days using ethanolic extracts of fruits of *Acacia nilotica* and flowers of *Calotropis procera* before sacrifice. The stomach of the animals was harvested, processed for histological investigation and photomicrographs taken.

**Place and Duration of Study:** Department of Biochemistry, Faculty of Pure and Applied Sciences, Federal University Wukari, between August 2022 and January 2023.

**Results:** Photomicrograph of the gastric tissue of normal rats showed normal epithelial lining with mucosa and submucosa appearing unremarkable. Photomicrograph section of gastric tissue of rat administered aspirin only showed moderate ulceration of the epithelial lining. Photomicrograph of gastric tissues of rats administered both plant extracts showed moderate to severe ulcerations of the epithelial lining with unremarkable mucosa and submucosa.

**Conclusion:** The results of this study showed that treatment of stomach ulcer in albino rats caused by administration of excess dose of aspirin with ethanolic extracts of fruits of *Acacia nilotica* and flowers of *Calotropis procera* did not heal the stomach ulcer in the albino rats after 5 days and 14 days treatment.

**Keywords:** *Acacia nilotica*; aspirin; *Calotropis procera*; histology; medicinal plant; stomach ulcer.

## 1. INTRODUCTION

Herbal medicine is a source of new discoveries in developing nations, as new drugs lead to diverse healthcare challenges and the synthesis of new formulations. When compared to other avenues of drug discovery, traditional medicine had contributed immensely to many novel therapeutic compounds for preventive and curative medicine [1]. Medicinal herbs are commonly used as an alternative remedy by people in developing nations. Hundreds of plants have traditionally been utilised throughout Africa to manage and control opportunistic infections [1]. In rural areas of underdeveloped countries, medicinal plants are still the primary source of medication. About 80% of people in developing countries utilise traditional medicines for healthcare [2,3].

An ulcer is a disease that affects both the external and internal viscera of the human body. It can manifest as an open sore in the epithelial cell lining or a deep lesion in a specific region that vitiates and leads to bleeding, resulting in a bleeding sore or bleeding ulcer [4]. Ulcers have been identified as one of the leading cause of death in the United States. Due to the increased use of nonsteroidal anti-inflammatory medicines (NSAIDs) such as aspirin (which are known to cause ulcers), gastrointestinal (GI) bleeding is still a significant clinical concern [5]. Stomach ulcers affect 5-10% of the world's population, according to estimates, a gastric or duodenal epithelial rupture that extends beyond the muscularis mucosa layer, an imbalance between mucosal protective factors (such as mucous production, bicarbonate secretion, and blood

flow) and mucosal aggressive factors (such as acid and pepsin) causes this [6]. Despite the fact that ulcers are commonly detected and recognised, asymptomatic ulcers remain a serious disease that can cause long-term harm to the gastrointestinal tract. With the discovery of *Helicobacter pylori* in 1982, the conventional concept of ulcer formation changed dramatically. The causes and pathogenesis of ulcers have improved since the discovery of *H. pylori*, and treatment protocols have evolved. The assumption that ulcers are caused by an acid-driven mechanism has been replaced by the belief that ulcers are caused by a combination of factors such as *H. pylori* infection and use of NSAIDs, such as aspirin [5].

Aspirin is perhaps the most commonly used nonsteroidal anti-inflammatory drug (NSAID). As further evidence of its benefits in primary and secondary prevention of cardiovascular events emerges, the usage of low-dose daily aspirin, often in the range of 75–325 mg/d, continues to rise. However, the danger of gastrointestinal (GI) problems such as ulceration and GI bleeding restrict aspirin's usefulness in disease prevention [7]. Aspirin was originally developed to relieve pain and inflammation, but its antiplatelet qualities have made it a popular treatment for preventing cardiovascular disease. Standard aspirin doses of 500 to 1,000 mg per day are typically prescribed for inflammatory disorders and pain relief, whereas antiplatelet doses of 75 to 325 mg per day are commonly prescribed for primary and secondary prevention of cardiovascular and cerebrovascular events [5].

*Acacia nilotica* is a tree that grows up to 20 metres tall, with a trunk diameter of 60 cm and a dense canopy, *Acacia nilotica* grows from sea level to over 2000 metres in India's plains of Andhra Pradesh and Maharashtra. It can resist temperatures as low as -1 °C and as high as 50 °C, however it is frost susceptible when young. The annual rainfall ranges from 250 to 1500 millimetres. During dry season, the trees are mostly deciduous, while riverine species can be virtually evergreen [8]. There are nine subspecies of *A. nilotica*, with six in the African Tropics and three in the Indian Subcontinent. *A. nilotica* has three subspecies in the Sahel region of West Africa: subsp. *nilotica*, subsp. *tomentosa*, and subsp. *adstringens* [9]. It is a medium-sized, virtually evergreen tree with a spreading crown and a short trunk. The bark is dark brown to practically black in colour and is extensively fissured or fractured longitudinally. The primary rachis bears glands, and the leaves are 2-pinnate. Stipular spines come in a variety of shapes and sizes. Leaflets are glabrous and subsessile. Its flowers are golden-yellow and fragrant, forming supplementary clusters of 2-5 heads in long-stalked globose heads. Its pods are stalked, flat, compressed, and contracted between the circular seeds, measuring 7.5-15.0 cm in length [8].

*Calotropis procera* is an evergreen, soft-wooded perennial shrub with a height of up to 2.5 metres (maximum 6 m). The bark is light grey, corky, and furrowed. The root is simple, branching, and woody at the base, with a fissured, corky bark, and branches with a deep, thick root and few branches [10,11]. The leaves are opposite-

decussate, simple, subsessile, and exstipulate, with a delicate layer of soft hairs that can sting. Flowers are shallow bell-shaped, like a campanula, bracteate, complete, bisexual, actinomorphic, pentamerous, hypogynous, pedicellate, multiflowered, umbellate, peduncled cymes with axillary or terminal inflorescence, and pedicellate, multiflowered, umbellate, peduncled cymes with axillary or terminal inflorescence [10,11]. The fruit is a sub-globose to obliquely ovoid follicle that is simple, fleshy and inflated. Seeds are abundant, tiny, flat, obovate, compressed with silky white pappus at one end, and 3 cm or longer in length [10,11].

The leaves have been used in sun worship since the Vedic era. Hindu healers employed the root bark's secretions to cure skin illnesses, coughs, intestinal worms, ascites, and anasarca, as well as enlargements of the abdominal viscera, among other things. Its milky juice was thought to be a harsh purgative and caustic [12]. The flowers were thought to help with digestion, catarrh, and hunger. Elephantiasis was also treated with the root bark. The juice was sometimes administered to women to induce abortion and was used for infanticide. The milky fluid was used by tanners to remove hair from hides [13]. The sensitive leaves are often employed in the treatment of migraines [12]. The presence of cardenolides made all portions of the plant have the potential to be hazardous (cardiac glycosides). The latex was found to be the richest in cardenolides, which has been previously documented. Cardenolides 162 mg/g dry weight and 2 mg/g total dry weight are found in the plant's leaf, according to research [11].



**Fig. 1. Fruits of *Acacia nilotica***



**Fig. 2. *Calotropis procera***

## **2. MATERIALS AND METHODS**

### **2.1 Plant Materials**

Dried fruits of *Acacia nilotica* was purchased from old market in Wukari, Nigeria. It was ground into powder. Fresh flowers of *Calotropis procera* was collected from Anguwan Roger Road, Wukari, Nigeria. It was air-dried at room temperature and then ground into powder. The chemical constituents of the ground samples were extracted using 70% ethanol.

### **2.2 Plant Extraction**

Seventy percent (70%) ethanol was prepared and was used to soak the two ground samples (fruits of *Acacia nilotica* and flowers of *Calotropis procera*) separately. The mixtures were filtered after 48 hours. The filtrates were concentrated using a water bath set at 68°C in order to eliminate the ethanol. The concentrated extract was prepared using normal saline before administration to the test animals.

### **2.3 Animals Care and Management**

Seventy (70) healthy male albino Wister rats (about 8 weeks old) were used for this experiment. The rats were purchased from Modibbo Adama University Yola, Adamawa State, Nigeria and were transported and housed in animal house of Biochemistry Department, Federal University Wukari, Nigeria. The rats were maintained under standard laboratory conditions

and were allowed free access to standard diet and water *ad libitum*. They were allowed to acclimatize for 14 days before the experiment.

### **2.4 Aspirin Used**

Aspirin (in tablet form) was obtained from a pharmacy in Wukari, Nigeria. Normal saline was used to prepare acetylsalicylic acid solution and was administered at a single dose of 500 mg/kg body weight orally to 24 hours fasted rats.

### **2.5 Experimental Design**

Seventy (70) healthy male albino rats were used for this experiment. The animals were randomly distributed into seven (7) groups with ten animals in each group. They received the plant extracts and aspirin orally as stated in Table 1.

Aspirin was given as a single dose of 500 mg/kg body weight to 24 hours fasted rats for induction of stomach ulcer. The animals were allowed to stay for 12 hours before the start of treatment. The ethanolic extracts of the two plant parts were administered to the animals for 5 days and 14 days respectively before sacrifice.

### **2.6 Animal Sacrifice**

Five albino rats from each group were sacrificed after 5 days treatment with the plant part extracts, while the remaining five rats in the groups were sacrificed after 14 days of treatment with the plant part extracts. The stomach of the

**Table 1. Administration of aspirin and plant extracts**

Group	1	2	3	4	5	6	7
Treatment	Normal control	Negative control: Aspirin (500 mg/kg)	Positive control: Aspirin (500 mg/kg) + Omeprazole (20 mg/kg)	Aspirin (500 mg/kg) + <i>Acacia nilotica</i> fruit extract (200 mg/kg)	Aspirin (500 mg/kg) + <i>Acacia nilotica</i> fruit extract (400 mg/kg)	Aspirin (500 mg/kg) + <i>Calotropis procera</i> flower extract (200 mg/kg)	Aspirin (500 mg/kg) + <i>Calotropis procera</i> flower extract (400 mg/kg)

animals were harvested for histological analysis. Animal ethics was approved by the ethical department, Federal University Wukari, Nigeria.

### 2.7 Histopathological Study of the Stomach

The stomach of the animals were harvested and fixed in 10% formalin, dehydrated in gradual ethanol (50-100%), cleared in xylene, and embedded in paraffin wax. The sections, which were 5-6 mm thick was then prepared using rotary microtome (Leica RM 2125 RTS, Singapore) and stained with hematoxylin and eosin dye for microscopic observation of histopathological changes in the stomach. The stomach sections were evaluated based on the severity of the ulceration.

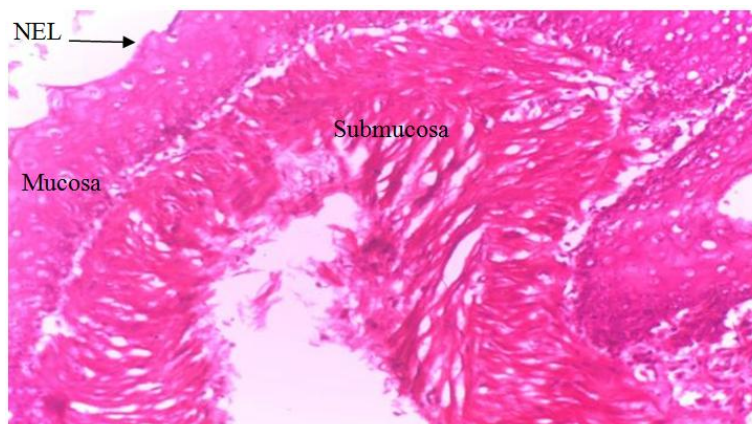
### 3. RESULTS AND DISCUSSION

Histological analysis results of the stomach of the Animals after Five Days Treatment has been depicted in Figs. 3-9.

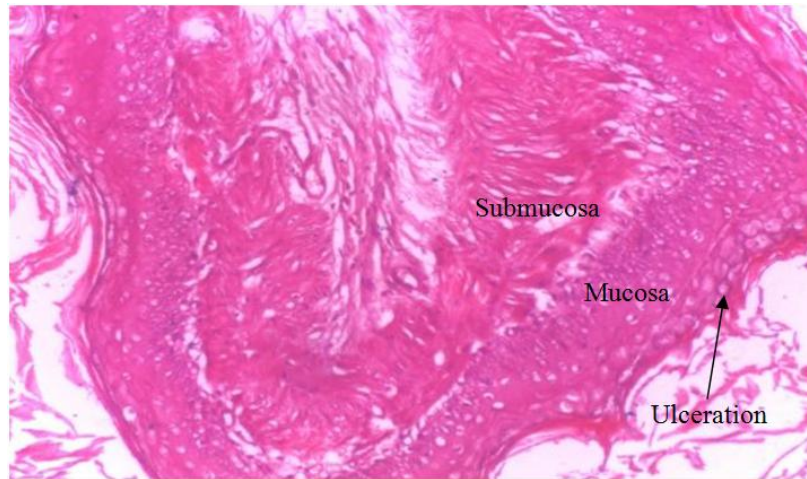
Histological analysis results of the stomach of the animals after fourteen days treatment has been depicted in Figs. 10-16.

Ulcer and its complications have shown striking geographical variations in incidence and prevalence across the globe embodying the different types that include peptic and gastric ulcers among others, which are consistent with the linings of the stomach and duodenum [14]. This current study examines the effects of ethanolic extracts of fruits of *Acacia nilotica* and flowers of *Calotropis procera* on aspirin-induced stomach ulcer in albino rats.

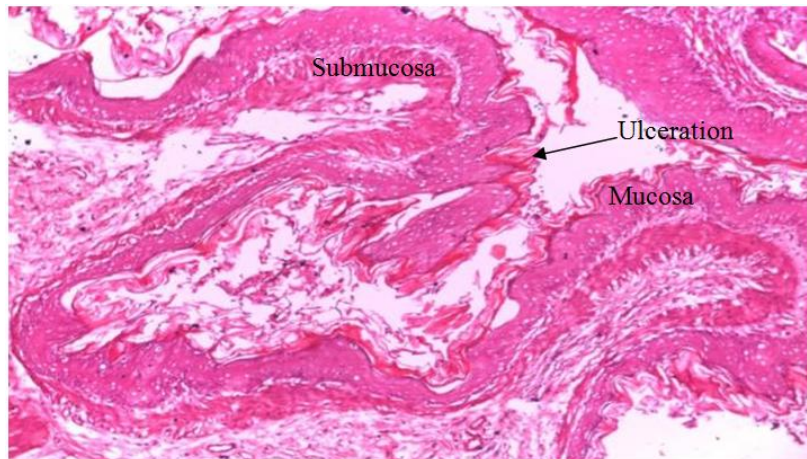
Histopathology of stomach of normal control rats for both 5 days and 14 days showed normal cyto-architecture of the cells with a normal epithelial, mucosa and submucosa layers (Fig. 3 and 10). Aspirin administration in group 2 animals at the end of 5 days showed a moderate ulceration on the epithelial lining with normal layers of mucosa and submucosa (Fig. 4), likewise after 14 days of the administration (Fig. 11). This confirms the ulcer inducing effect of administration of excess dose of aspirin. This ulceration may be due to erosion of the surface epithelial cells, a decrease in mucosal thickness and loss of gastric mucosa integrity as reported by Yomna et al. [15]. NSAIDs act by inhibiting the metabolism of arachidonic acid by both cyclooxygenase and lipoxygenase enzymes pathways.



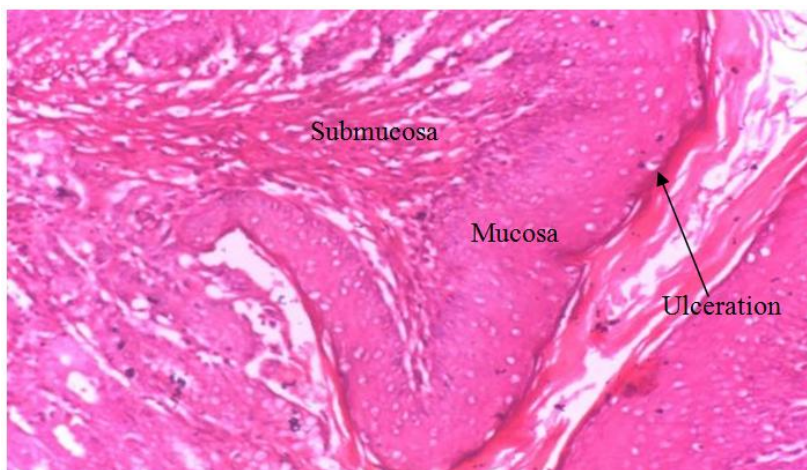
**Fig. 3. Photomicrograph of section of gastric tissue of normal control rat (group 1)**



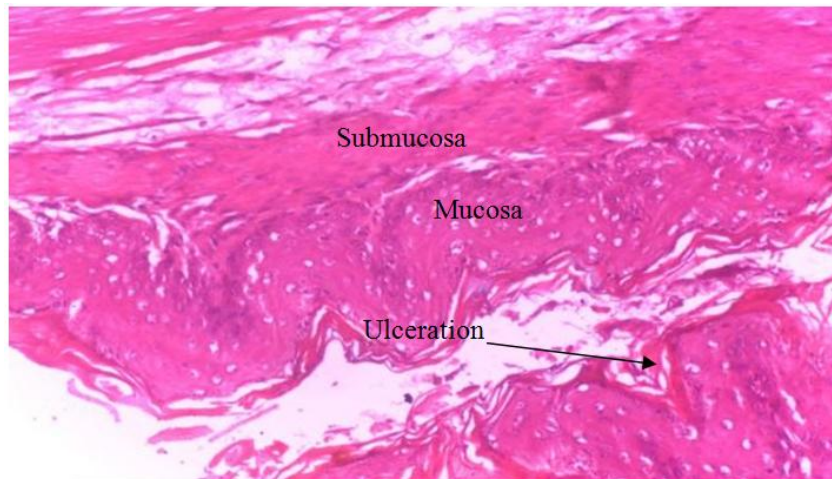
**Fig. 4. Photomicrograph of section of gastric tissue of rat administered aspirin (500mg/kg) only (group 2)**



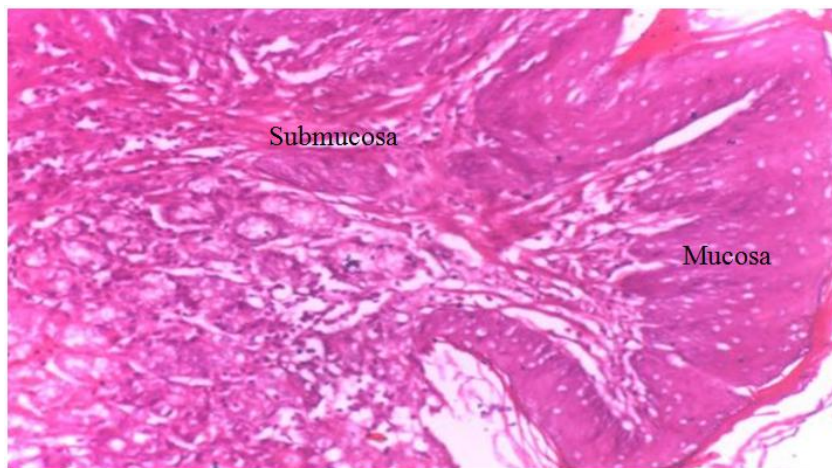
**Fig. 5. Photomicrograph of section of gastric tissue of rat administered aspirin (500mg/kg) and omeprazole (20mg/kg) (group 3)**



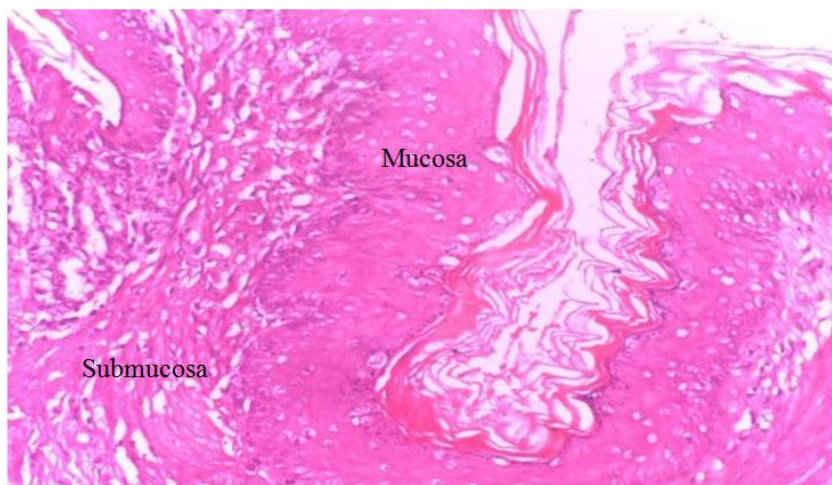
**Fig. 6. Photomicrograph of section of gastric tissue of rat administered aspirin (500mg/kg) and *Acacia nilotica* fruit extract (200mg/kg) (group 4)**



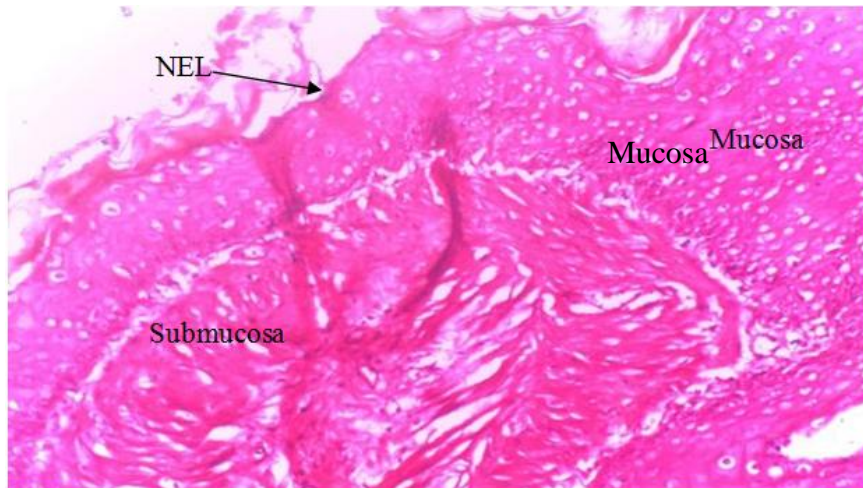
**Fig. 7. Photomicrograph of section of gastric tissue of rat administered aspirin (500mg/kg) and *Aca.cia nilotica* fruit extract (400mg/kg) (group 5)**



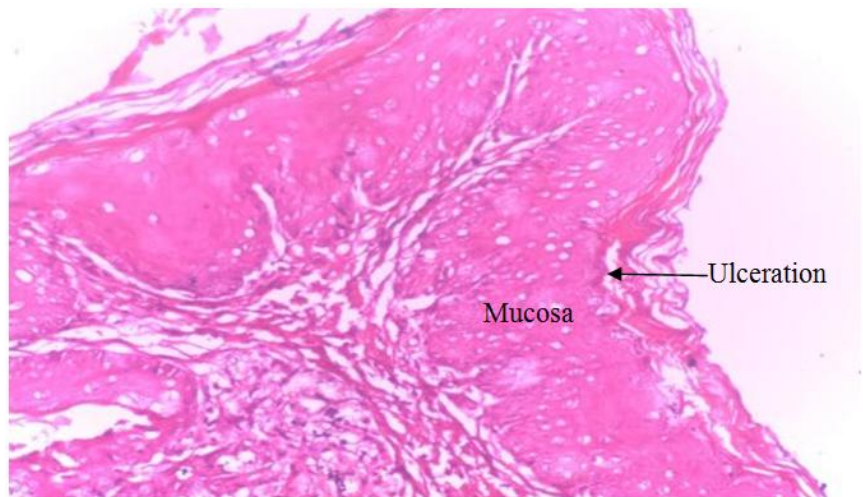
**Fig. 8. Photomicrograph of section of gastric tissue of rat administered aspirin (500mg/kg) and *Calotropis procera* flower extract (200mg/kg) (group 6)**



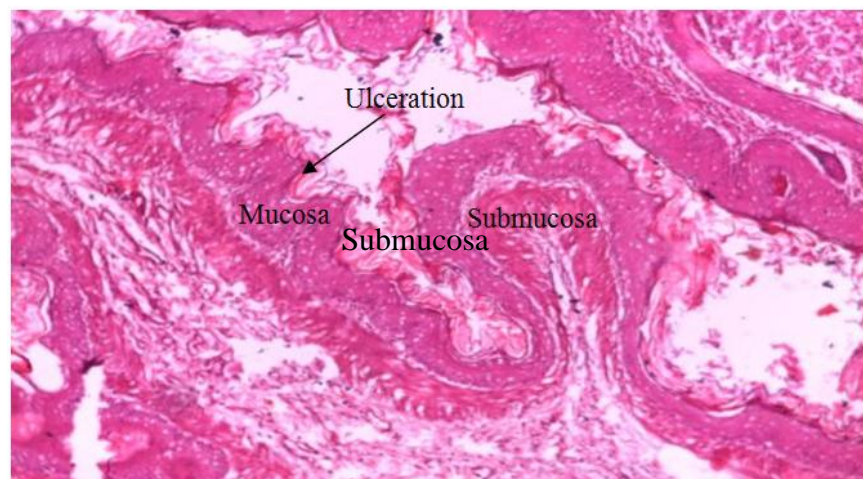
**Fig. 9. Photomicrograph of section of gastric tissue of rat administered aspirin (500mg/kg) and *Calotropis procera* flower extract (400mg/kg) (group 7)**



**Fig. 10. Photomicrograph of section of gastric tissue of normal control rat (group 1)**

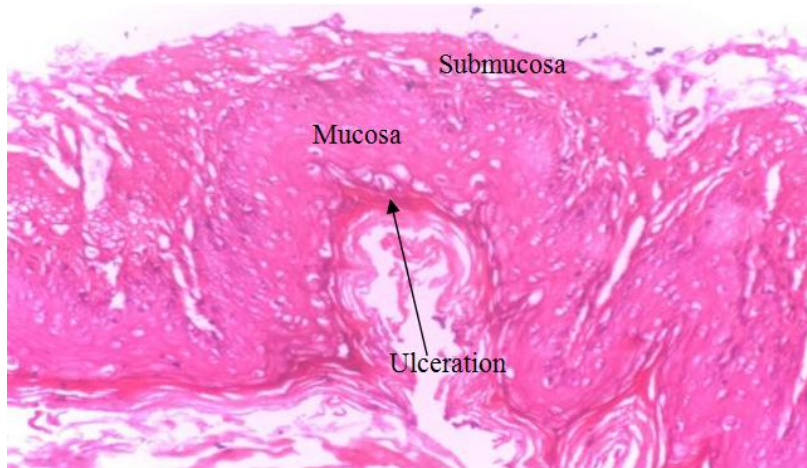

**Fig. 11. Photomicrograph of section of gastric tissue of rat administered aspirin (500mg/kg) only (group 2)**

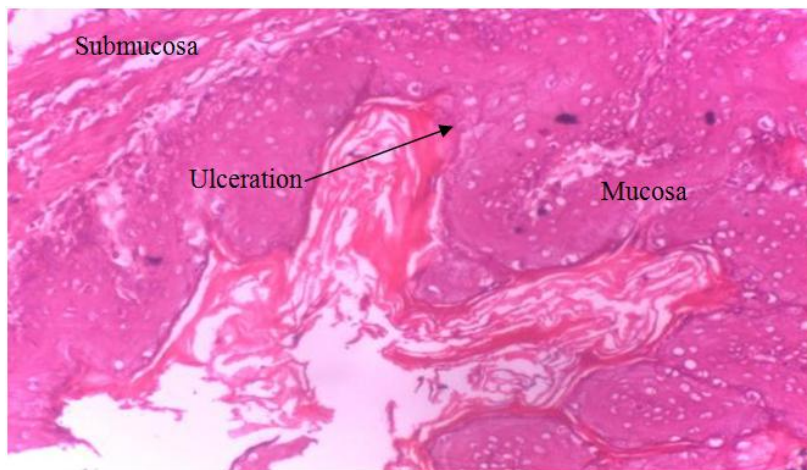


**Fig. 12. Photomicrograph of section of gastric tissue of rat administered aspirin (500mg/kg) and omeprazole (20mg/kg) (group 3)**

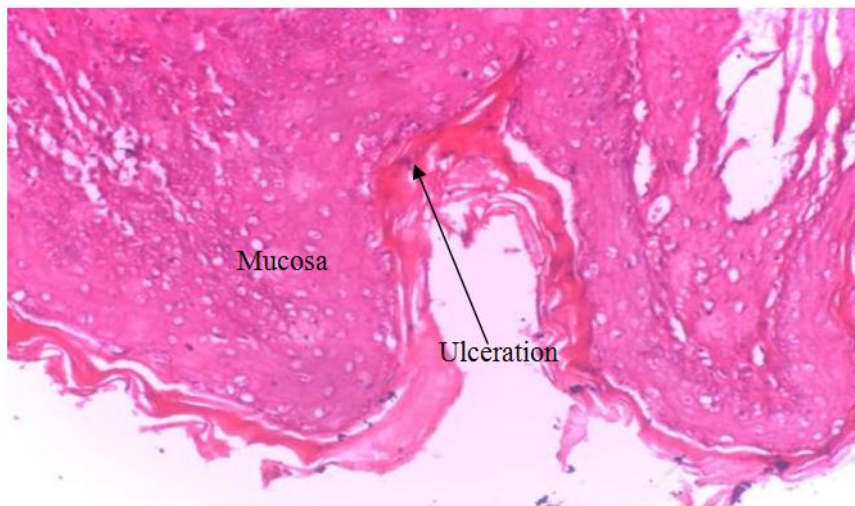



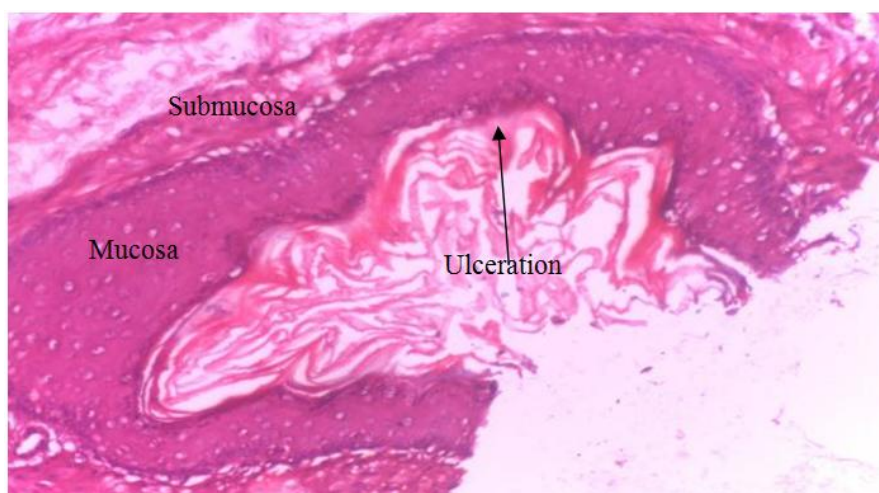**Fig. 13. Photomicrograph of section of gastric tissue of rat administered aspirin (500mg/kg) and *Acacia nilotica* fruit extract (200mg/kg) (group 4)**



**Fig. 14. Photomicrograph of section of gastric tissue of rat administered aspirin (500mg/kg) and *Acacia nilotica* fruit extract (400mg/kg) (group 5)**



**Fig. 15. Photomicrograph of section of gastric tissue of rat administered aspirin (500mg/kg) and *Calotropis procera* flower extract (200mg/kg) (group 6).**



**Fig. 16. Photomicrograph of section of gastric tissue of rat administered aspirin (500mg/kg) and *Calotropis procera* flower extract (400mg/kg) (group 7)**

Administration of fruits extracts of *Acacia nilotica* for both 5 days and 14 days treatment at 200 mg/kg body weight and 400 mg/kg body weight respectively showed severe ulcerations on the epithelial lining with thin mucosa and submucosa layers. A study carried out by Aisha et al. [16] showed that *A. nilotica* flowers extract healed ulcers caused by *H. pylori*. Also, a study by Vijay and Rajesh [17] and Azeemat and Elizabeth [18] reported that the extract of young seedless pods of *A. nilotica* have antiulcer activity in pylorus ligation, swimming stress and indomethacin-induced ulcer rat models. The findings of these studies are in contrast with the result of this present study that showed no healing effect in male albino rats treated with ethanolic extract of fruits of *A. nilotica*.

Treatment with *Calotropis procera* flowers extract for both 5 days and 14 days treatment also showed a severe ulceration on the epithelial lining of the stomach with the mucosa and submucosa layers appearing thin. A review by Abdulrahman [19] showed that *C. procera* in both 200 mg/kg and 400 mg/kg body weight doses have demonstrated a dose dependent antiulcer activity after 5 days of administration following acetic acid-induced ulcer. It is also possible that the different results observed in this study when compared with few other research reports may be as a result of the chemical substance used for induction of the ulcers and how the animals' bodies tolerate them. The class, amount and types of chemical constituents extracted by the chemicals used in the plant extraction processes may contribute the effects of the extracts observed, since the effects of the extracts

depends on their constituents. The histopathology result from this study showed that the ethanolic extracts of fruits of *Acacia nilotica* and flowers of *Calotropis procera* did not exert a positive effect in healing of aspirin-induced stomach ulcer in albino rats.

#### 4. CONCLUSION

The results of this study showed that treatment of stomach ulcer in albino rats caused by administration of excess dose of aspirin with ethanolic extracts of fruits of *Acacia nilotica* and flowers of *Calotropis procera* did not heal the stomach ulcer in the albino rats after 5 days and 14 days treatment. The photomicrographs seen in the study showed moderate to severe ulcerations after treatment with the two plant parts extracts. This implies that both plant part extracts may not be good in the management of stomach ulcer caused by excess dose of aspirin.

#### ACKNOWLEDGEMENT

I want to acknowledge the contributions of all authors in developing the manuscript. This research is sponsored by all authors.

#### COMPETING INTERESTS

Authors have declared that no competing interests exist.

#### REFERENCES

1. Yakubu EO, Imo C, Christopher S, John A, Daniel SA. Effects of ethanolic leaf and stem-bark extracts of *Adansonia Digitata* in

- alloxan-Induced diabetic wistar rats. Journal of Pharmacology and Toxicology. 2020;15:1-7.
2. Nagpal M, Sood S. Role of curcumin in systemic and oral health: An overview. Journal of Natural Science, Biology, and Medicine. 2013;4(1):3.
  3. Manfo FP, Nantia EA, Kuete V. Hepatotoxicity and hepatoprotective effects of African medicinal plants. Toxicological Survey of African Medicinal Plants. 2014;9(2):33-355.
  4. Devansh M. Ulcer - review on types, anti-ulcer drugs, anti-ulcer medicinal plants, anti-ulcer drug market, diagnostics and current global clinical trials status. Inventi Rapid: Pharmacy Practice. 2016; (2):1-8.
  5. Byron C, Kenneth W. Gastrointestinal ulcers, role of aspirin, and clinical outcomes: Pathobiology, diagnosis, and treatment. Journal of Multidisciplinary Healthcare. 2014:7137-7146.
  6. Ray-Offor E, Opusunju KA. Current status of stomach ulcer disease in Port Harcourt metropolis, Nigeria. African Health Science. 2020;20(3):1446-1451.
  7. Ajani A, Winter K, Okawara G, Donohue J, Pisters P, Christopher H. Phase II trial of prooperative chemoradiation in patients with localised gastric adenocarcinoma: Quality of combined modality therapy and pathologic response. Journal of Clinical Oncology. 2006;24(24):2004-2780.
  8. Brijendra S, Meena AK, Uttam-Niranjan AK, Yadav AK, Nagaria KA, Gaurav VG, Singh R. A review on *Acacia nilotica* Linn. and its ethnobotany, phytochemical and pharmacological profile. Research Journal of Science and Technology. 2010;2(4):67-71.
  9. Amadou I, Soulé M, Salé A. An overview on the importance of *Acacia nilotica* (L.) willd. ex del.: A review. Asian Journal Residence. 2020;5:12-18.
  10. Anwar I, Sadeeqa S. Stomach ulcer: Mini review with respect to case. International Journal of Vaccines and Vaccination. 2018;5(2):39-40.
  11. Gaurav P, Neelam B. *Calotropis procera*: A phytochemical and pharmacological review. Thai Journal of Pharmaceutical Sciences. 2016;40(3):115-131.
  12. Verma R, Satsangi GP, Shrivastava JN. Ethno-medicinal profile of different plant parts of *Calotropis procera* (Ait.). Research of British Ethnobotanical Leaflet. 2010;14:721-742.
  13. Ahmed KK, Rana AC, Dixit VK. *Calotropis* species (ascelpediaceae): A comprehensive review. Pharmacology Magazine. 2005;1:48-52.
  14. Patrick A, Samson F, Madusolumuo O. Antiulcerogenic effects of aqueous stem-bark extracts of *Pterocarpus erinaceus* on indomethacin-induced ulcer in albino rats. Journal of Biochemistry and Cell Biology. 2018;1(2):1000107.
  15. Yomna IM, Eman A, Abd E. Spirulina ameliorates aspirin-induced gastric ulcer in albino mice by alleviating oxidative stress and inflammation. Biomedicine and Pharmacotherapy. 2018;109:314-321.
  16. Aisha MH, Husam Q, Abdulrahman SB, Naif KB, Tarek MA. Pharmacological evaluation of *Acacia nilotica* flower extract against *Helicobacter pylori* and human hepatocellular carcinoma *in vitro* and *in silico*. Journal of Functional Biomaterials. 2023;14(4):237-255.
  17. Vijay KB, Rajesh KG. Gastroprotective effect of *Acacia nilotica* young seedless pod extract: Role of polyphenolic constituents. Asian Pacific Journal of Tropical Medicine. 2012;12:523-528.
  18. Azeemat TA, Elizabeth AB. Antiulcer effect of *Acacia nilotica* seedpod aqueous extract on experimentally induced ulcer. African journal of Biological Sciences. 2012;4(2): 86-95.
  19. Abdulrahman MD. A systematic review on the biological evaluation of *Calotropis procera* (aiton) dryand. Future Journal of Pharmaceutical Sciences. 2023;9:16.

© 2023 Muhammad et al.; This is an Open Access article distributed under the terms of the Creative Commons Attribution License (<http://creativecommons.org/licenses/by/4.0>), which permits unrestricted use, distribution, and reproduction in any medium, provided the original work is properly cited.

Peer-review history:

The peer review history for this paper can be accessed here:  
<https://www.sdiarticle5.com/review-history/99691>