



A Study Protocol for Evaluation of Clinical and Functional Outcomes of Forearm Bone Fractures Treated by Screw Intramedullary Nail

Parth Shah ^{a*} and Nareshkumar Dhaniwala ^{a#}

^a *Department of Orthopaedics, Jawaharlal Nehru Medical College, Datta Meghe Institute of Medical Sciences Deemed to be University, India.*

Authors' contributions

This work was carried out in collaboration between both authors. Both authors read and approved the final manuscript.

Article Information

DOI: 10.9734/JPRI/2021/v33i64A35758

Open Peer Review History:

This journal follows the Advanced Open Peer Review policy. Identity of the Reviewers, Editor(s) and additional Reviewers, peer review comments, different versions of the manuscript, comments of the editors, etc are available here: <https://www.sdiarticle5.com/review-history/80843>

Study Protocol

Received 25 October 2021
Accepted 29 December 2021
Published 30 December 2021

ABSTRACT

Background: The incidence of forearm fractures has increased rapidly over the past few years as a consequence of industrial accidents, interpersonal assaults, road traffic accidents, sports injuries, etc. The advantages of Closed or mini-open reduction using screw intramedullary nail and stable fixation include short duration and low-cost of surgery, 3 point fixation, and satisfactory union of the fracture. This study aims to assess the clinical, radiological, and functional outcomes of forearm bone fractures treated by Screw intramedullary nails.

Materials and Methods: This will be a Prospective Observational study conducted on 25 skeletally mature patients reporting to the dept. of Orthopedics, AVBRH, Wardha. Patients with fracture of radius and ulna together or single bone diaphyseal fracture in the forearm will be enrolled in the study. The findings will be analyzed using parameters proposed by Anderson et. al. scoring system for functional assessment and radiological union. Statistical analysis would be done to conclude the findings.

Expected Results: Significant clinical, radiological, and functional outcomes of forearm bone fractures treated by Screw intramedullary nail are expected.

[‡]Post Graduate Resident;

[#]Professor;

^{*}Corresponding author: E-mail: parthshah6396@gmail.com;

Keywords: Radius and ulna; forearm fracture; screw intramedullary nail; radiological outcomes; diaphyseal fractures.

1. INTRODUCTION

The forearm fractures approximately occur in 2 to 4 per 10,000 adults. In the past few years due to rapid industrial development, an increase in the incidence of assault, road traffic accidents, athletic injuries, fall on an outstretched hand and direct blow to the forearm, forearm bone fractures are being commonly encountered in the orthopedic outpatient department. The forearm fractures can result in difficulty in activities of daily living when treated inadequately [1-6]. Hence anatomical reduction becomes far more important and restoring the soft tissue and vascularity is equally important to achieve the maximum functional outcome.

Achieving anatomical reduction with compression at the fracture site, rotational stability and length is very important for gaining good rotational function. Mal-aligned fractures affect the movement of the elbow and forearm. Early joint mobilization is critical for preventing joint stiffness. Periosteal blood flow has to be maintained by less damage to soft tissue during open surgery. Open reduction and internal fixation with Dynamic compression plate (DCP) is a standard technique for all forearm bone fractures [7]. Many modern modalities of plate Osteosynthesis such as locking plate and limited contact plate have been introduced, but DCP is still a popular option among many surgeons [8]. Encouraging results recorded with recent developments in clinical management and instrumentation have resulted in an extension of surgical guidelines for such fractures, as well as a controversy about the technique of choice. Previous studies suggest that plate fixation provides positive outcomes for all bone forearm fractures but it has drawbacks such as longer processing time, greater blood loss, damage of soft tissue, stripping of periosteal, radioulnar synostosis, neurovascular injury, nonunion, and infection [9-14].

Intramedullary nailing is an alternative fixation method for both bone forearm fractures with the advantage of lesser operative time, less blood loss, less soft tissue injury, no periosteal stripping, and minimal fracture biology disturbance. The intramedullary nail can also be used in radius or ulna open diaphysis fracture [15,16].

Forearm both bone fractures can be treated with different intramedullary implants like a square nail, flexible elastic nail, rush nail, malleable wires, or nails. Closed reduction and internal fixation with these nails have been in use for many years [1,2]. Screw intramedullary nail is another innovative implant giving us the benefit of intramedullary nail along with providing reasonable stability of the fractures. In the forearm, both bones are stabilized with an intra-osseous membrane giving it stability in all functions of the forearm. Any disruption of this membrane causes loss of rotation therefore, restoration of anatomy becomes important to regain full function. . Maintaining the radial bow and ulnar length are important for good function of the forearm. The importance of supinator and pronator muscle function in the opposite directions have an importance during the fracture of forearms, like a fracture at proximal level results in the proximal fragment of supination and the distal fragment of pronation [3]. Open reduction and stable internal fixation help to maintain radial bow and achieve good primary bony union.

The distinct advantage of locked intramedullary nailing is the capacity of preventing metaphyseal shortening, comminuted, segmental diaphyseal forearm fractures [4,5], but the procedure is technically demanding and injury to the posterior interosseous nerve is reported. Closed or mini-open reduction of forearm bone fracture along with stable fixation using screw intramedullary nail gives us the advantages of low-cost implant, short duration of surgery, 3 point fixation of the fracture, and union at the fracture site with secondary callus. It is technically simple to use and better suited for patients of the rural area who many times have financial difficulty and are willing to accept slab immobilization for a few weeks.

The present study titled "Management of radius and ulna fractures by Screw- intramedullary nail in skeletally mature patients" is aimed to study the utility of Screw intramedullary nails in adult forearm fractures."

2. BIOMECHANICS OF FOREARM

The ulna is a relatively straight bone, but it makes the radius much more complex. Reference to the ulna moving around the radius

is frequently heard. The ulna is a relatively fixed strut around which the radius rotates in pronation and supination, pointing out the complexity and the importance of preserving the angles and curves in this bone, especially the lateral bow of the fracture of the radius. If this is not accomplished, full pronation and supination will not be achieved by the patient.

Technique for calculating the maximum radial bow quantity and position. The maximal radial bow is described by drawing a line from the bicipital tuberosity to the most ulnar part of the wrist radius. A perpendicular line from this line to the radius is drawn at the point of the highest radial bow, and the distance is measured in millimeters. The position of the radial bow is calculated by dividing the distance between the bicipital tuberosity and the maximum bow point by the total bow length. The meaning is displayed as a percentage of 50.0. This calculation corresponds with the result of treatment following fractures of both forearm bones.

Interosseous space lies between the shafts of the radius and the ulna. From their proximal origin at the radius and distal insertion at the ulna, the fibers of the interosseous membrane run obliquely across the interosseous space. Thickened and measuring around 3.5 cm in width, The central portion of the interosseous membrane indicated that the triangular fibrocartilage complex incision alone reduced relative stability by eight percent.

Interosseous membrane proximal to the central band and incision of the complex of triangular fibrocartilage reduced stability by just eleven percent. However, the central band incision decreased stability by seventy-one percent. If the radial head is wounded and needs resection, A constant structure is the thickened central band of the interosseous membrane and accounts for most of the longitudinal radius support.

2.1 Aim and Objectives

2.1.1 Aim

1. Management of radius and ulna fracture by Screw intramedullary nail in skeletally mature patients.

2.1.2 Objectives

1. To study the clinical and functional outcome of forearm bone fracture treated by Screw intramedullary nail

2. To analyze the radiological outcome of forearm bone fractures.

3. MATERIALS AND METHODS

The study will be conducted on skeletally mature patients having a radius and ulna fracture together in the forearm or single bone diaphyseal fracture in the forearm, in the Department of Orthopedics, at Jawaharlal Nehru Medical College and Acharya Vinoba Bhave Rural Hospital, Sawangi, Wardha. The duration of the study will be from November 2020 to October 2022.

Sample Size: Twenty-five (25) Patients would be included in the present study.

Study Type: Prospective Observational Study.

Data Collection Period: November 2020 to August 2022.

Data Analysis: September 2020 to October 2022.

3.1 Inclusion Criteria

1. Skeletally mature patients of either sex
2. Shaft fracture of radius and ulna together.
3. Fracture shaft radius or ulna in the diaphysis

3.2 Exclusion Criteria

1. Pathological fracture
2. Patient unfit for surgery and significant comorbidity affecting the bone healing
3. Grade 3 Compound fracture
4. Fractures in the metaphyseal regions of radius and/or ulna

3.3 Method of Collection Data

All the adult patients having fracture both bone or single bone forearm shaft fracture and presenting in the Department of Orthopedics, at Jawaharlal Nehru Medical College and Acharya Vinoba Bhave Rural Hospital, Sawangi, Wardha during the study period November 2020 to October 2022 will be included in the study after written informed consent.

The patients will be subjected to detailed history and examination after admission to the orthopedic ward. The clinical diagnosis will be confirmed by x-ray forearm AP and lateral view

and primary splint by above elbow slab will be given. The examination will include a comparison with the normal side in terms of Neurovascular status and evaluation to rule out compartment syndrome.

Radiological Evaluation - Plain radiographs would include anterior-posterior and lateral view for detailed diagnosis and preoperative planning for surgical management. The fracture is categorized according to AO/OTA classification. The patient will be treated by Screw intramedullary nail fixation after the fracture reduction by closed manipulation or mini-open reduction if required. The position will be checked C-arm image intensifier in both AP and lateral plane and fixation will be done using the standard prescribed method of insertion of Screw intramedullary nail. A full set of nails and instruments would be available before the surgery. Postoperatively Inj. ceftriaxone 1gm IV BD will be given for 3 days. Patients will be discharged 4 days after surgery and stitch removal will be done 10-12 days postoperatively. For a period of six to eight weeks after removal of the stitch, the above elbow slab continues. 500mg of elemental calcium and 500 mg of ascorbic acid will be given to all patients for 6 weeks.

3.4 Follow Up

Cases will be reviewed at four weeks, eight weeks, twelve weeks, and twenty-four weeks to

assess the fracture clinically and radiologically. The function of the forearm, elbow, and wrist will be noted.

Follow-up time, clinical features like the presence of pain, tenderness of the surgical scar, tenderness at the fracture site, instability, and range of movements would be observed and documented. Different radiological features such as callus formation or healing, fracture reduction, widening and depression of articular surfaces, varus and valgus collapse will be observed and documented. Complications related to the Screw intramedullary nail such as nail back out, irritation of tendons at the site of the screw, and infection will be noted and managed suitably.

Union with a minimum of at least 3 cortices in AP and lateral views on follow-up radiographs would be recorded and noted. Anderson criteria will be used to decide results at the last follow-up.

4. RESULTS

1. With the aid of parameters suggested, the result will be evaluated by Anderson et al. scoring [17] system for functional assessment and radiological union. Statistical analysis would be done to conclude the findings (table 1).
2. The fractures will be classified using AO/OTA classification (Fig. 1).

Table 1. Functional assessment and radiological union

Result	Union	Flexion and extension at wrist joint	Supination and pronation
Excellent	Present	<10° loss	<25% loss
Satisfactory	Present	<20° loss	<50% loss
Unsatisfactory	Present	<30° loss	<50% loss
Failure	Non-union with or without loss of motion		

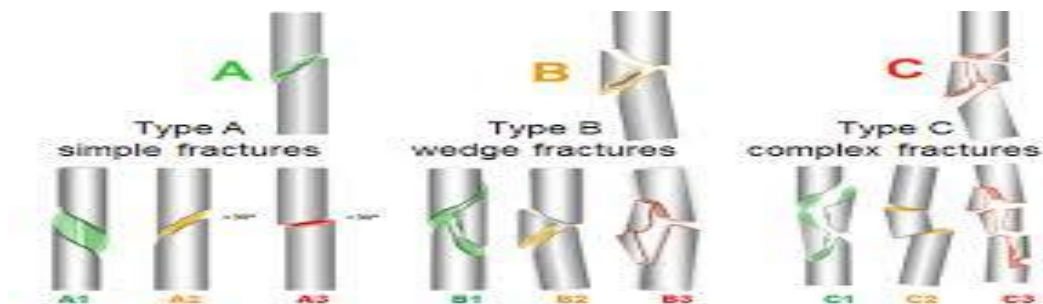


Fig. 1. Fractures

Type 22-A Diaphyseal, Simple, Ulna / Radius
A1 Ulna simple fracture, Radius bone intact
A2 Radius simple fracture, Ulna bone intact
A3 Both bone radius & ulna simple fracture

Type 22-B Diaphyseal, wedge fracture, Ulna / Radius
B1 Ulna wedge fracture, Radius bone intact
B2 Radius wedge fracture, Ulna bone intact
B3 Both bone radius & ulna wedge fracture

Type 22-C Diaphyseal, complex fracture, Ulna / Radius
C1 Complex of ulna bone
C2 Complex of the Radius bone
C3 Complex comminuted fractures of both bone

5. DISCUSSION

For forearm bone fractures conservative and /or inadequate treatment is often fraught with many complications. Open reduction and fixation of the plate is one of the widely used recovery strategies for fractures in the forearm. Different writers have shown well for outstanding union rate outcomes. Results with K-rishner wires for intramedullary nailing, Steinman pins have been disappointing, and Rush pins a strong non-union rate. The elastic Rush pins obey and hold the radial curve and provide stability by three-point fixation, but with a thin nail. The rotatory stability fails to fix it. The ends of nails Move Acting as a possible tendon irritant around the wrist, Street implemented a square that needed early elimination. Design to increase stability and healing of fractures which the non-union rates have altered significantly. But the elastic intramedullary nail screw acts on the three-point fixation theory and the preservation of the Radial bow, explaining the problems with the DRUJ. An interlocking nail with distal static fixation is the screw nail and the proximal end of a complex subchondral bone situation. soft tissue integrity of the limb is achieved by dynamic effect, the exercise that is initiated after the process, thus establishing the dynamic effect. The screwed end of the locks for the nails. The ulna and radius at the metaphyseal end impart relative stability which assists in the formation of a good callus. An angulation in any plane of fewer than ten degrees. It has been shown that there is no interference with any restriction in the range of motion of forearms. The Periosteal Secondary Callus Because of the stress shielding properties, forming is evident due to Of the implant. Nonunion, Neurovascular Iatrogenic

compartment syndrome was not observed. Few of the related studies were reported [18-20]. Similar studies were reviewed [21,22]. Awasthi et al. reported a study on fracture of distal end radius managed with Antegrade K/I-Wire fixation [23]. Burhani et al. reported the impact of immersive virtual reality-based rehabilitation on functional independence and health-related quality of life after distal radius fracture [24-28].

6. CONCLUSION

Closed reduction and internal fixation of forearm fractures by screwing intramedullary nails restore the proximity of the nails. The natural touch of the pieces that are broken. The intramedullary nail screw efficiently handles a nail's spinning forces as well as migration. This offers excellent clinical results for isolated fractures of both bones and both forearm bones in adults.

CONSENT

As per international standard or university standard, patients' written consent will be collected and preserved by the author(s).

ETHICAL APPROVAL

As per international standard or university standard written ethical approval will be collected and preserved by the author(s).

COMPETING INTERESTS

Authors have declared that no competing interests exist.

REFERENCES

1. Crenshaw AH, Zinar DM, Pickering RM. Intramedullary nailing of forearm fractures. Instr Course Lect. 2002;51:279-89.
2. Patrick J. A study of supination and pronation, with especial reference to the treatment of forearm fractures. J Bone Joint Surg Am. 1996;28(4):737-48.
3. Gao H, Luo CF, Zhang CQ, Shi HP, Fan CY, Zen BF. Internal fixation of diaphyseal fractures of the forearm by interlocking intramedullary nail: Short-term results in eighteen patients. J Orthopedics Trauma. 2005;19:384-91.
4. De Pedro JA, Garcia-Navarrete F, Garcia De Lucas F, Otero R, Oteo A, Lopez-Duran Stern L. Internal fixation of ulnar

- fractures by locking nail. *Clin Orthop Relat Res.* 1992;283:81-5.
5. Gadegone W, Salphale YS, Lokhande V. Screw elastic intramedullary nail for the management of adult forearm fractures. *Indian Journal of Orthopaedics.* 2012 Feb;46:65-70.
 6. Anderson LD, et al. Compression-plate fixation in acute diaphyseal fractures of the radius and ulna. *J Bone Joint Surg Am.* 1975;57(3):287–297.
 7. Russel TA. *Campbell's Operative Orthopaedics.* 8th edition. 2nd Volume. Classification of Diaphyseal fractures. 2017;728-730.
 8. Saikia KC, Bhuyan SK, Bhattacharya TD, Borgohain M, Jitesh P, Ahmed F. Internal fixation of fractures of both bones forearm: Comparison of locked compression and limited contact dynamic compression plate. *Indian J Orthop.* 2011;45(5):417.
 9. Naiman PT, Schein AJ, Siffert RS. Use of ASIF compression plates in selected shaft fractures of the upper extremity. A preliminary report. *Clin Orthop.* 1970;71:208-16.
 10. Duncan R, Geissler W, Freeland AE, Savoie FH. Immediate internal fixation of open fracture of the diaphysis of the forearm. *J Orthop Trauma.* 1992;6:25-31.
 11. Reilly TJ. Isolated and combined fractures of the diaphysis of the radius and ulna. *Hand Clin.* 2002;18:179-94.
 12. Knight RA, Purvis GD. Fractures of both bones of the forearm in adults. *Bone Joint Surg Am.* 1949;31:755-64.
 13. Moore TM, Klein JP, Patzakis MJ, Harvery JP. Results of compression- plating of Galeazzi fractures. *J Bone Joint Surg Am.* 1985;67:1015-21.
 14. Evans EM. Rotational deformity in the treatment of fractures of both bones of the forearm. *J Bone Joint Surg.* 1945;27(3):373-9.
 15. Langkamer VG, Ackroyd CE. Internal fixation of forearm fractures in the 1980s: Lessons to be learnt. *Injury.* 1991;22:97-102.
 16. Moerman J, Lenaert A, De Coninck D, Haeck L, Verbeke S, Uyttendaele D, et al. Intramedullary fixation of forearm fractures in adults. *Acta Orthop Belg.* 1996;62:34-40.
 17. Smith H, Sage FP. Medullary fixation of forearm fractures. *J Bone Joint Surg Am.* 1959;39:91-8.
 18. Newey ML, Ricketts D, Roberts L. The AO classification of long bone fractures: an early study of its use in clinical practice. *Injury.* 1993;24(5):309–312.
 19. James, Spencer L, Chris D Castle, Zachary V Dingels, Jack T Fox, Erin B Hamilton, Zichen Liu, Nicholas L S Roberts, et al. "Global Injury Morbidity and Mortality from 1990 to 2017: Results from the Global Burden of Disease Study 2017. *Injury Prevention.* 2020;26(1):96–114. Available:<https://doi.org/10.1136/injuryprev-2019-043494>.
 20. Murray, Christopher J L, Cristiana Abbafati, Kaja M Abbas, Mohammad Abbasi, Mohsen Abbasi-Kangevari, Foad Abd-Allah, Mohammad Abdollahi, et al. Five Insights from the Global Burden of Disease Study 2019. *The Lancet.* 2020;396(10258):1135–59. Available:[https://doi.org/10.1016/S0140-6736\(20\)31404-5](https://doi.org/10.1016/S0140-6736(20)31404-5)
 21. Murray, Christopher J L, Aleksandr Y Aravkin, Peng Zheng, Cristiana Abbafati, Kaja M Abbas, Mohsen Abbasi-Kangevari, Foad Abd-Allah, et al. Global Burden of 87 Risk Factors in 204 Countries and Territories, 1990–2019: A Systematic Analysis for the Global Burden of Disease Study 2019. *The Lancet.* 2020;396(10258):1223–49. Available:[https://doi.org/10.1016/S0140-6736\(20\)30752-2](https://doi.org/10.1016/S0140-6736(20)30752-2)
 22. Dhankar S, Bele A. A Case of Fracture Shaft Femur in a Patient with Transtibial Amputation. *Journal of Datta Meghe Institute of Medical Sciences University.* 2019;14(4):394–96. Available:https://doi.org/10.4103/jdmimsu.jdmimsu_190_19
 23. Reddy S, Dhaniwala N. Diaphyseal fractures in pediatric age group in Rural Area: A Demographic Study. *Journal of Datta Meghe Institute of Medical Sciences University.* 2019;14(3):189–91. Available:https://doi.org/10.4103/jdmimsu.jdmimsu_79_19
 24. Awasthi A, Saoji K, Palsodkar P. To Study the Outcome/Analysis of Fracture Distal End Radius Managed with Antegrade k/l-Wire Fixation. *International Journal of Current Research and Review.* 2020;12(22):S-137-S-139. Available:<https://doi.org/10.31782/IJCRR.2020.SP68>
 25. Burhani T, Naqvi WM. Impact of Immersive Virtual Reality-Based Rehabilitation on

- Functional Independence and Health Related Quality of Life after Distal Radius Fracture: A Study Protocol for a Single Blinded Randomized Control Trial.” *Journal of Critical Reviews*. 2020;7(9):559–63. Available:<https://doi.org/10.31838/jcr.07.09.111>
26. Nagrale AV, Glynn P, Joshi A, Ramteke G. The efficacy of an integrated neuromuscular inhibition technique on upper trapezius trigger points in subjects with non-specific neck pain: A randomized controlled trial. *Journal of Manual & Manipulative Therapy*. 2010 Mar 1;18(1):37-43.
27. Agrawal A, Cincu R, Goel A. Current concepts and controversies in the management of non-functioning giant pituitary macroadenomas. *Clinical Neurology and Neurosurgery*. 2007 Oct 1;109(8):645-50.
28. Chole RH, Gondivkar SM, Gadbail AR, Balsaraf S, Chaudhary S, Dhore SV, Ghonmode S, Balwani S, Mankar M, Tiwari M, Parikh RV. Review of drug treatment of oral submucous fibrosis. *Oral Oncology*. 2012 May 1;48(5):393-8.
29. Korde SD, Basak A, Chaudhary M, Goyal M, Vagga A. Enhanced nitrosative and oxidative stress with decreased total antioxidant capacity in patients with oral precancer and oral squamous cell carcinoma. *Oncology*. 2011;80(5-6):382-9.

© 2021 Shah and Dhaniwala; This is an Open Access article distributed under the terms of the Creative Commons Attribution License (<http://creativecommons.org/licenses/by/4.0>), which permits unrestricted use, distribution, and reproduction in any medium, provided the original work is properly cited.

Peer-review history:

The peer review history for this paper can be accessed here:
<https://www.sdiarticle5.com/review-history/80843>