



Late Presentation of Mayer-Rokitansky-Kuster-Hauser Syndrome in the Tropics-Northern Nigeria

I. A. Yakasai^{1*}, S. M. Daneji¹, A. Natasha¹ and E. M. Yunus¹

¹Department of Obstetrics and Gynaecology, Bayero University Kano/Aminu Kano Teaching Hospital Kano, Nigeria.

Authors' contributions

This work was carried out in collaboration between all authors. All authors read and approved the final manuscript.

Article Information

DOI: 10.9734/BJMMR/2015/11384

Editor(s):

- (1) E. Umit Bagriacik, Department of Immunology, Gazi University, Turkey.
(2) Jimmy T. Efirid, Department of Public Health, Director of Epidemiology and Outcomes Research East Carolina Heart Institute, Brody School of Medicine, Greenville, North Carolina, USA.

Reviewers:

- (1) Anonymous, Hospital Universitario y Politécnico La Fe, Valencia, Spain.
(2) Georgios Androutopoulos, Department of Obstetrics and Gynecology, University of Patras, Medical School, Greece.
(3) Alan Mu Kang Wai, Research and training unit, Faculty of Dentistry, University of Malaya, Malaysia.
(4) Anonymous, Hacettepe University, Turkey.

(5) Anonymous, Universidade Federal de Minas Gerais – UFMG – Belo Horizonte (MG), Brasil.
Peer review History: <http://www.sciencedomain.org/review-history.php?iid=715&id=12&aid=6682>

Case Report

Received 13th May 2014
Accepted 25th September 2014
Published 24th October 2014

ABSTRACT

Mayer-Rokitansky-Kuster-Hauser syndrome is a congenital malformation characterized by failure of the mullerian duct to develop, resulting in missing of the uterus and upper part of the vagina in women showing normal development of secondary sexual characteristics and a 46, XX karyotype. It is the second most common cause of primary amenorrhoea after Turner's syndrome. A 30 year old nulliparous lady who has been married for 13years presented with history of primary amenorrhoea. Examination revealed a young lady, with normal female pubic and axillary hair distribution, and breast was at tanner stage 4. Pelvic examination showed a normal sized clitoris, labia majora and minora, normal urethra, and blind ended vagina extending to about 7cm. Abdomino-pelvic USS revealed both kidneys normal in position and size, hypoplastic uterus measuring 1.05cm in antero-posterior diameter, left adnexium and pouch of Douglas were normal. Buccal and peripheral blood smear show Barr bodies and drumstick appendages suggested karyotype is XX. She subsequently had diagnostic laparoscopy which revealed a streak of thickened ligament at the position of the uterus. Both ovaries and their ligaments were visualised with a follicular cyst on the right ovary. We

*Corresponding author: Email: ibrahimyakasai57@hotmail.com;

made a diagnosis of mullerian agenesis. The couple were counselled and the poor prognosis for fertility explained since they did not seem to have significant problem with intercourse. Gestational surrogacy is a viable treatment option for patients with Rokitansky syndrome and was offered to this patient, but couldn't afford it due to the prohibitive cost of the procedure.

Keywords: Primary amenorrhea; hypoplastic uterus; laparoscopy; gestational surrogacy.

1. INTRODUCTION

The Mayer-Rokitansky-Kuster-Hauser (MRKH) syndrome is characterized by congenital aplasia of the uterus and the upper part (2/3) of the vagina in women showing normal development of secondary sexual characteristics and a normal 46, XX karyotype [1]. Müllerian agenesis is the second most common cause of primary amenorrhea after Turner's syndrome [2]. Its incidence is 1:5000 female births [3]. The majority of cases appear to be sporadic; however familial cases have also been described. Type I MRKH syndrome is characterized by an isolated absence of the uterus and proximal two thirds of the vagina, whereas type II or MURCS (Müllerian duct aplasia, Renal dysplasia and Cervical Somite anomalies) is marked by other malformations, including vertebral, cardiac, urologic (upper tract), and otologic anomalies [4].

Mayer-Rokitansky-Kuster-Hauser syndrome usually remains undetected until the patient presents with primary amenorrhea despite normal female sexual development. It has psychological consequences, but its anatomical defects are surgically treatable. The condition affects females and has no racial predisposition. The aetiology of MRKH syndrome has remained quite unclear until recently, when it was found that the spectrum of malformations encountered suggests a developmental field defect, involving organ systems which are closely related during embryogenesis [1]. Several hypotheses have been postulated for the underlying mechanism. These include an activating mutation of either the gene for the antimüllerian hormone or the gene for the antimüllerian hormone receptor, resulting in the inappropriate production of antimüllerian hormone or the receptor which then acts as if it was bound to the hormone [5]. We report a case of MRKH from our centre.

2. CASE PRESENTATION

The hospital ethical committee gave approval for this case report and consent was obtained from the patient as well.

A 30 year old nulliparous lady presented with history of primary amenorrhoea, breast development, pubic and axillary hair. No history of abnormal facial hair growth, change in voice, nipple discharge, heat or cold intolerance, no history of weight loss or gain.

2.1 History

She has been married for 13 years, had dyspareunia which has reduced over the years, with some degree of sexual satisfaction. No history of postcoital bleeding. No history of pelvic surgery or use of contraceptive pills. Patient had used traditional medications to induce menses at the age of 14 years without success. She has sought for orthodox care in peripheral hospitals few years after marriage with no improvement, before subsequently referred to this facility.

There was no history of hearing impairment, polydactyl, cardiac or renal abnormalities known to the patient. She gave no history of any medical disorder.

She is the first child of a consanguineous marriage in a monogamous family. There were no abnormalities detected at birth. Younger sibling attained menarche at the age of 14 years and currently has a child. No history of primary amenorrhoea or infertility in the family.

2.2 Physical Characteristics

On examination she was found to be a young lady well preserved, with a height of 1.46m and weight of 38.6kg (BMI 18.1 kg/m²). Had five digits with no skeletal deformity noted. There was normal female pubic hair distribution, and axillary hair tanner stage 5. Breast was at tanner developmental stage 4.

She had a pulse rate of 84 beats per minute, blood pressure of 110/80mmHg heart sounds were one and two only. There was no abnormality detected on chest examination.

The abdomen was full moves with respiration with no swelling or area of tenderness, pelvic

examination reveals a normal labia majora and minora, normal sized clitoris, blind ended vagina with stretched length of 7cm, bimanual examination reveals no mass palpable between examining fingers. There was a normally sited urethra and anus.

2.3 Investigations

Abdominopelvic USS showed both kidneys normal in position and size, hypoplastic uterus measuring 1.05cm in anteroposterior diameter, left adnexium and pouch of douglas within normal limits, right adnexium showed cystic swellings within the right ovary in keeping with follicular cyst. Routine hematological studies revealed haemoglobin level of 13.1 g/dl and serum creatinine level of 105 micromole/L. Buccal and peripheral blood smear show Barr bodies and drumstick appendages in over 10% of the cells, suggested karyotype is XX.

2.4 Treatments

She had examination under anaesthesia and diagnostic laparoscopy, which further confirmed normal sized clitoris, labia majora and minora, normal urethra, and blind ended vagina extending to about 7cm with normal skin surrounding the vagina. A streak of thickened ligament was seen at the position of the uterus (Fig. 1). Both ovaries and their ligaments were visualised with a follicular cyst on the right ovary measuring 2x3 cm. A diagnosis of müllerian agenesis was made. Postoperatively, the couple were counselled and the poor prognosis for fertility was explained. The option of neovagina was offered to the patient, but she declined, since there was no coital problem, at the time of presentation. The most commonly used nonsurgical procedure is Frank's dilator method. It involves the application, first by the clinician and then by the patient herself, of vaginal dilators (Hegar candles), progressively increasing in length and diameter. Dilators are placed on the perineal dimple for at least 20 minutes a day. The whole process takes between six weeks and several months, with a success rate varying from 78% to 92%. Complications are rare and generally consist of urethritis, cystitis, vesico- or retro-vaginal fistula and secondary prolapse. As this non-operative approach is non-invasive and often successful, it is recommended as a first-line therapy. However, it can be applied only when the vaginal dimple is deep enough (2–4 cm) as in this woman. This would have been the best to offer to this patient. Unfortunately in our setting

these dilators are difficult to come by and the patient was advised on continues regular coitus. Recent advances have also shown that, gestational surrogacy is a viable treatment option for patients with Rokitansky syndrome. Such patients should be well informed and supported to be able to have a family using their own genetic gametes. This was offered to this patient, but couldn't afford it due to the prohibitive cost of the procedure in the developing Nation like ours.

3. DISCUSSION

The syndrome of congenital absence of the vagina in association with an abnormal or absent uterus was first characterized by Mayer, Rokitansky, Kuster, and Hauser and Schreiner [5]. The syndrome has frequently been referred to as the Mayer-Rokitansky-Kuster-Hauser syndrome (MRKH). The syndrome is a congenital condition in which a genetic female is born with vaginal agenesis and a rudimentary or absent uterus. This condition affects a woman's ability to menstruate, to engage in penile-vaginal intercourse, and to bear children. Much has been published about how best to create a neovagina in women with MRKH, but little has been written about the psychological impact of MRKH and quality of life outcomes for women with the condition. The average age at diagnosis is from 10–18 years [6] which is lower than our patient age. This patient presented with history of primary amenorrhoea, and infertility which is a common presentation of patients with mullerian agenesis, but she presented late due to the poor health seeking behaviour of most of the patients in northern Nigeria compounded by her low educational status of primary school level only.

Mayer–Rokitansky–Küster–Hauser anomaly could have other associated malformations. Between 1975 and 2002, 25 patients with a diagnosis of MRKHA were identified at the Mayo Clinic and their charts were reviewed retrospectively [6]. Two of the 25 patients were found to have absence of one ovary, scoliosis (20%), unilateral renal agenesis (28%), non-vertebral skeletal anomalies (16%). In the MURCS association, four patients had cardiac defects (including truncus arteriosus, patent ductus arteriosus and patent foramen ovale, mitral valve prolapse, and mild mitral regurgitation). Patients with MRKHA should be search for associated cardiac defects, this was done in our patient but none was found.

Full anatomic examination is necessary to diagnose either type of MRKH syndrome. Complete uterus aplasia in the presence of two rudimentary horns linked by a peritoneal fold and normal Fallopian tubes correspond to isolated or MRKH type I syndrome as found in our patient. In order to make this diagnosis we carried out diagnostic laparoscopy and the findings are as in Fig. 1. Type II MRKH is characterized by uterine symmetric or asymmetric hypoplasia, accompanied by aplasia of one of the two horns coupled with tubal malformations such as hypoplasia or aplasia of one of the fallopian tubes.

Mullerian agenesis is the second most common cause of primary amenorrhoea after Turners syndrome [2,8]. The primary amenorrhea is due to the congenital absence of the upper two thirds of the vagina, the cervix, uterus and fallopian tubes which are derivatives of the Mullerian ducts [7]. Affected individuals are phenotypically female and have a normal female karyotype (46, XX) [8]. Our patient has had buccal and peripheral smear that suggested the karyotype to be 46XX. She had also developed secondary sexual characteristics indicating that the Levels of estradiol and the gonadotrophins are normal as well. It has been found out that the patterns of hormonal secretion by the ovaries are within normal limits even in the absence of the uterus. This patient has no other abnormality detected and an USS showed presence of both kidneys in contrast to the case reported with absence of the left kidney [9].

The aetiology of MRKH syndrome has remained quite unclear, although the spectrum of malformations encountered suggests a developmental field defect, involving organ systems which are closely related during embryogenesis [10,11]. More precisely, MRKH syndrome may be attributed to an initial affection of the intermediate mesoderm, consequently leading to an alteration of the blastema of the cervicothoracicsomites and the pronephric ducts [12].

These latter subsequently induce the differentiation of the mesonephroi and then the Wolffian and Müllerian ducts. The syndrome was initially considered to be of sporadic occurrence, suggesting the involvement of non-genetic/environmental factors such as gestational diabetes and thalidomide [12,13]. However, studies analysing available pregnancy histories failed to identify any association with drug use, illness, or exposure to known

teratogens [13]. Another explanation of the sporadic occurrence of the syndrome was the hypothesizes of a polygenic/multifactorial inheritance, characterized by a low recurrence risk for first-degree relatives [12].

Young women diagnosed with MRKH syndrome suffer from extreme anxiety and very high psychological distress when they are told they have no uterus and vagina and cannot bear children. Thus, it is recommended that the patient and family attend counselling before and throughout treatment [1]. The couple were fully counselled on these two main issues. A review of the extant literature published from 1955 to 2007 supports that surgical or non-surgical creation of a neovagina alone does not ensure a successful psychological outcome, psychological support at critical times can be helpful, and how professionals use language to discuss the condition may positively or negatively influence a female's experience of MRKH. This patient had had discussion done in her own vernacular in the presence of her husband who was around at all times for support. Creation of a adequate vagina is the objective of treatment of vaginal agenesis. Treatment should be deferred until the patient is contemplating sexual activity. Non-surgical creation of a vagina using serial vaginal dilators, in a method described by Frank and later modified by Ingram, is relatively risk-free but requires patient motivation and cooperation. Repetitive coitus [3] can also be used to create a functioning vagina as may be assumed from this case when she reported a history dyspareunia which has subsided with time and was having a satisfactory sex. The surgical treatment includes McIndoe technique, Williams vaginoplasty, rotational flap procedures, intestinal neovagina and Vecchietti technique [4], none was done in this patient because she has successfully overcome her sexual problem with repetitive and regular intercourse.

Current literature described the modified Abbe-McIndoe technique of vaginoplasty with split-thickness skin graft -A multi-holed, rigid plastic mold was inserted during surgery and was replaced after 8 to 10 days with a semi rigid silicone mold, which remained in place at least 6 months after operation or until the patient became sexually active. Because of the simplicity, low morbidity, and high success rate, it is recommended that modified Abbe-McIndoe technique is a procedure of choice for vaginoplasty. We have no experience of this procedure in our centre.

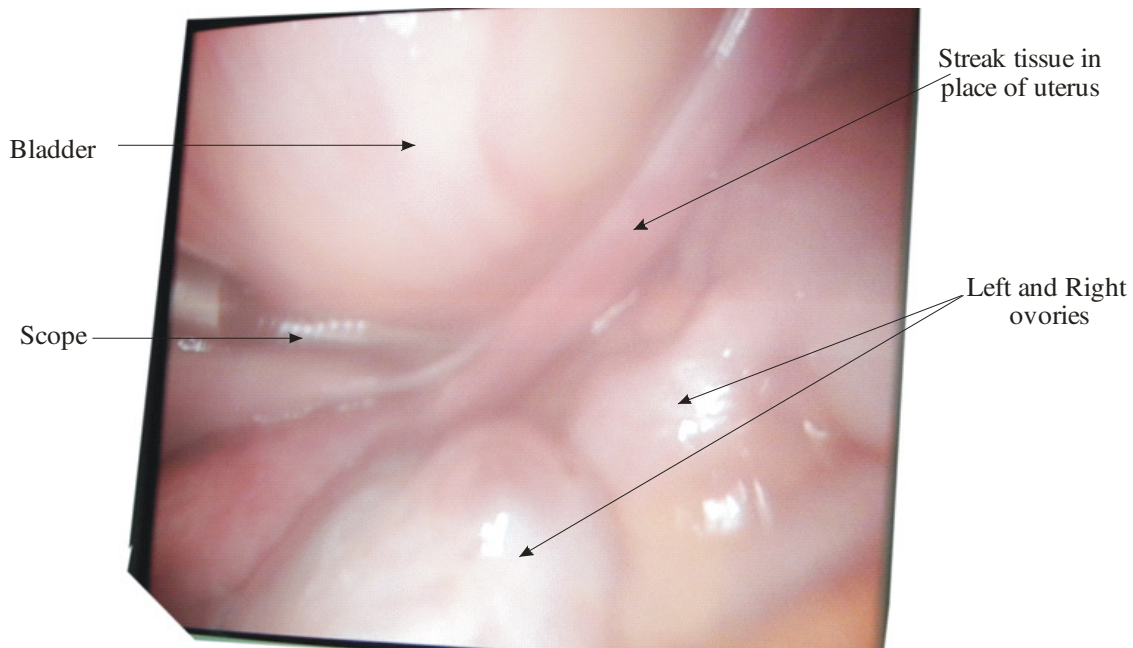


Fig. 1. Showed normal ovary and streak of tissue instead of uterus (Atypical form of Rokitansky syndrome)

Recent advances have shown that, gestational surrogacy is a viable treatment option for patients with Rokitansky syndrome [14]. Such patients should be well informed and supported to be able to have a family using their own genetic gametes. This was offered to this patient, but couldn't afford it due to the prohibitive cost of the procedure in the developing Nation like ours.

Ultimately, infertility will be the most difficult aspect of the disorder for the patient to accept. Nowadays medical technologies allow, in-vitro fertilization of their own eggs and to use surrogate pregnancy [15]. However, the risk for transmission of the disease cannot be accurately evaluated, since very little is currently known about genetics of the MRKH syndrome [12]. This strengthens the need for more research in the field.

The search for cure in MRKH continues, even in developed Nations [16,17,18,19,20]. In countries such as Nigeria most patients present late as in this case and only because of infertility. Majority of the women are happy once they can achieve some degree of sexual satisfaction as demonstrated in this couple. The issue of infertility is to some extent also helped in our setting with adoption as an option and many relatives around who would only be willing to let their children be adopted by such couples.

4. CONCLUSION

Our patient presented late with Rokitansky syndrome. She had a blind ended vagina, absent uterus and normal ovaries. The couple were counselled on the poor prognosis for fertility. Though gestational surrogacy is a viable option, these couple couldn't afford it

COMPETING INTERESTS

Authors have declared that no competing interests exist.

REFERENCES

1. Karine M, Laure C. Review Mayer-Rokitansky-Küster-Hauser (MRKH) syndrome. *Orphanet Journal of Rare Diseases*. 2007;2:13.
2. Okonofua F, Odunsi K (Eds). *Contemporary obstetrics gynecology for developing countries*. WHARC; 2003.
3. Decherney AH, Nathan L, Goodwin TM, Laufer N (Eds). *Current obstetrics and gynecology*. 10th Ed. Mc Graw Hill. 2007;549.
4. Kirsch AJ, Zuckerman AL. Mayer-Rokitansky Syndrome. Available: <http://emedicine.medscape.com/article/953>

